

National Liver Histopathology EQA Scheme

Circulation A1
December 2009

Circulation A1, meeting 10.12.09

- Present were 30 members and 9 guests
- Of members present, 6 had been unable to view the slides and send responses because the slides had not been sent to them in time. If you have slides at a busy time, please send straight on to the next person in your cell and inform Sophia, who will re-arrange the circulation.
- Responses with marks deducted are shown in brown italics in the slides below, and explanation and discussion on the following slide.

Case 326

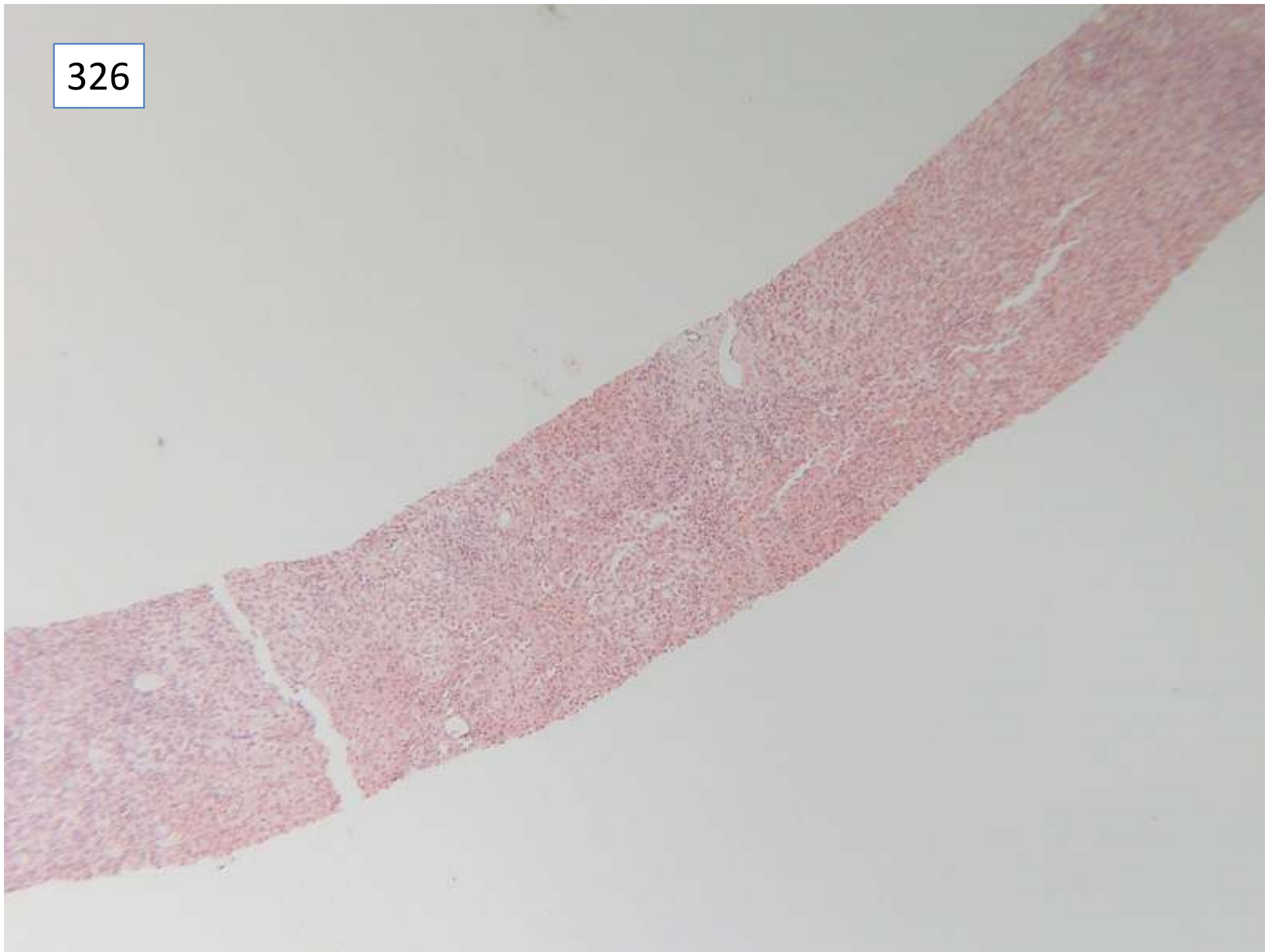
Female 76 years

4 week history of painless jaundice.

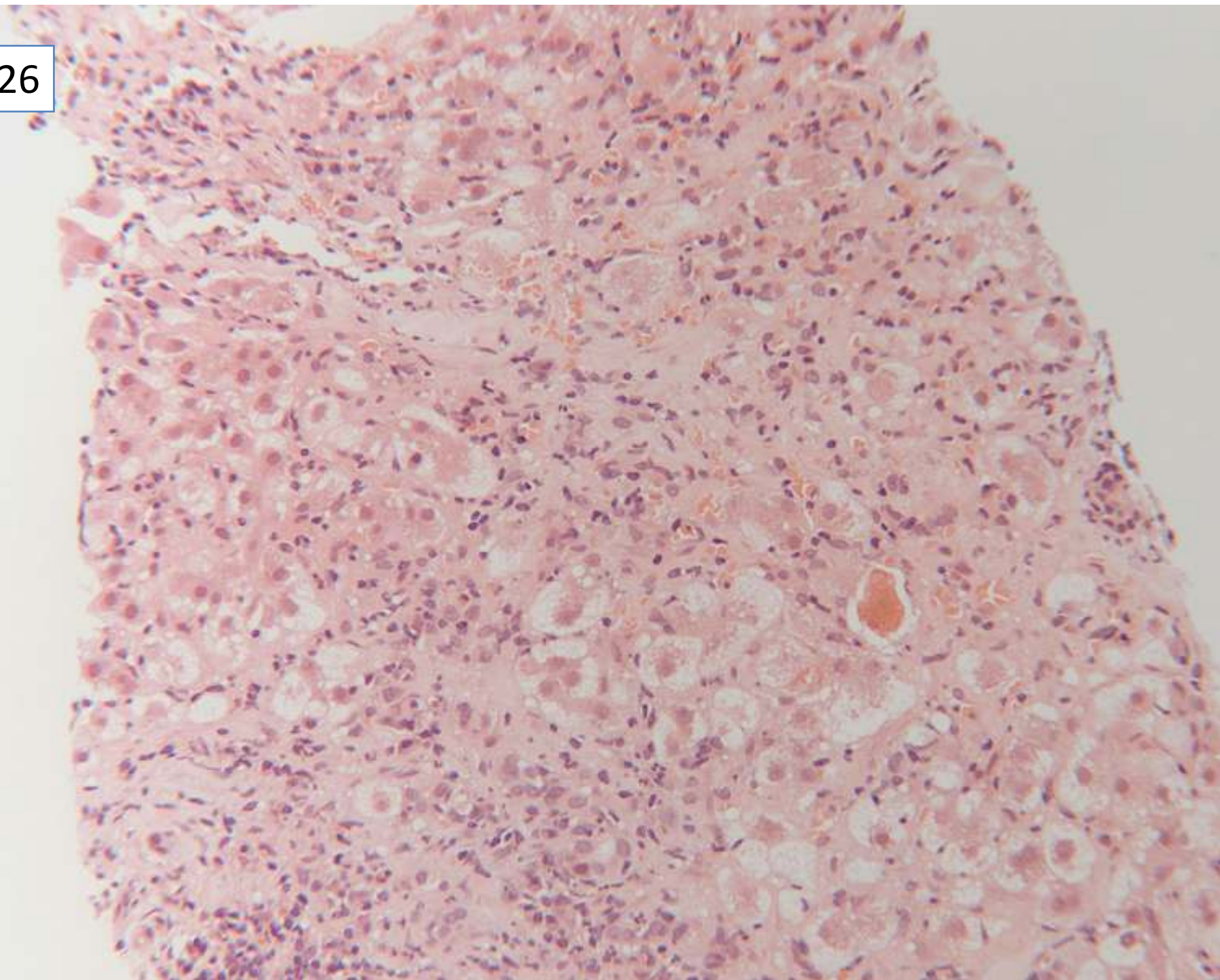
Bili 12 $\mu\text{mol/L}$, ALT 40 iu/L , AP 349 iu/L , alb 41 g/l , GGT 498 ui/L , negative for HBV, HCV,.

Immunology: ANA 160, other serology negative (AMA, LKM etc.) IgG 23.4 g/L (6-13) IgA 8.73 g/L (0.8-3)

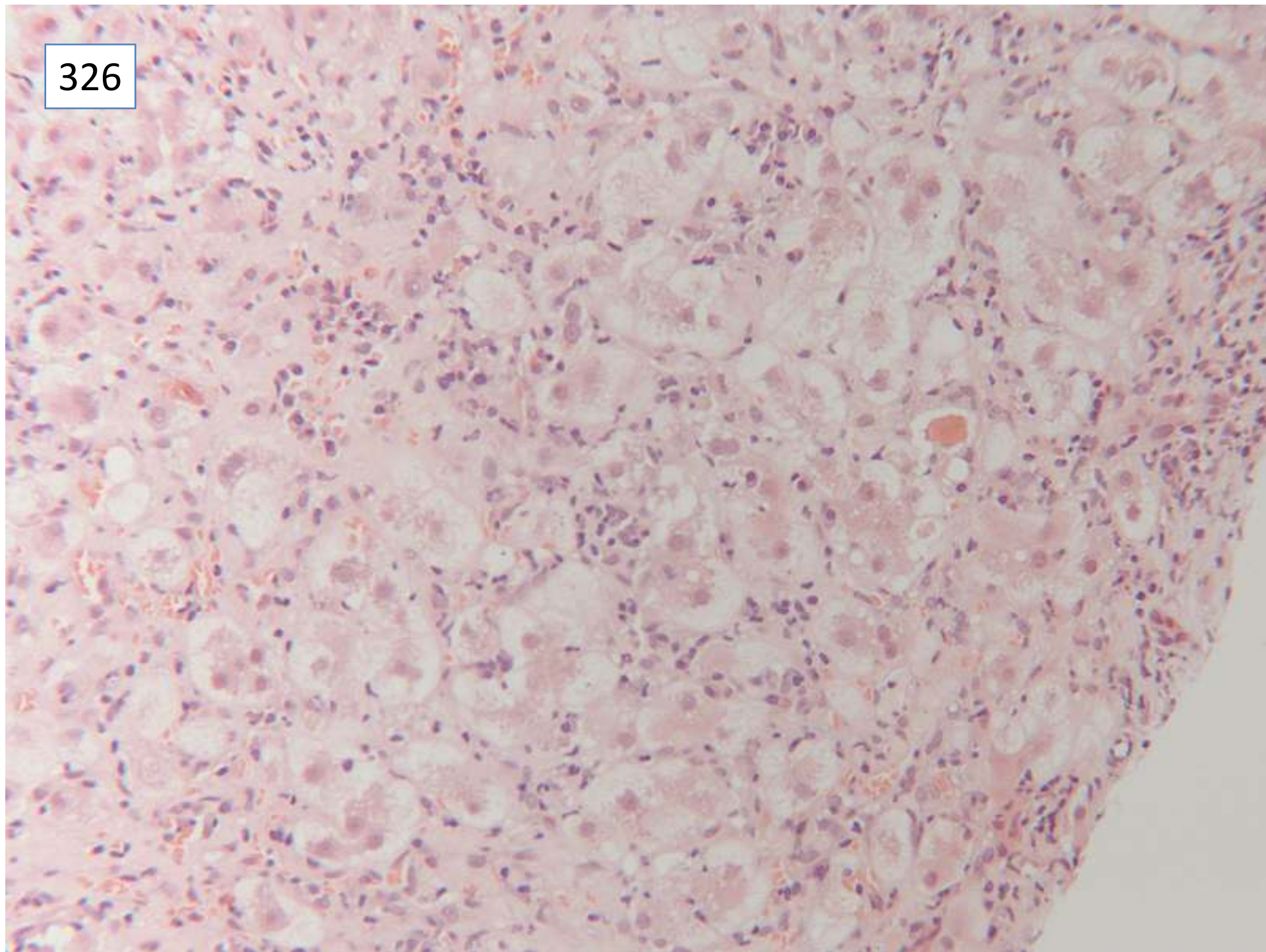
326



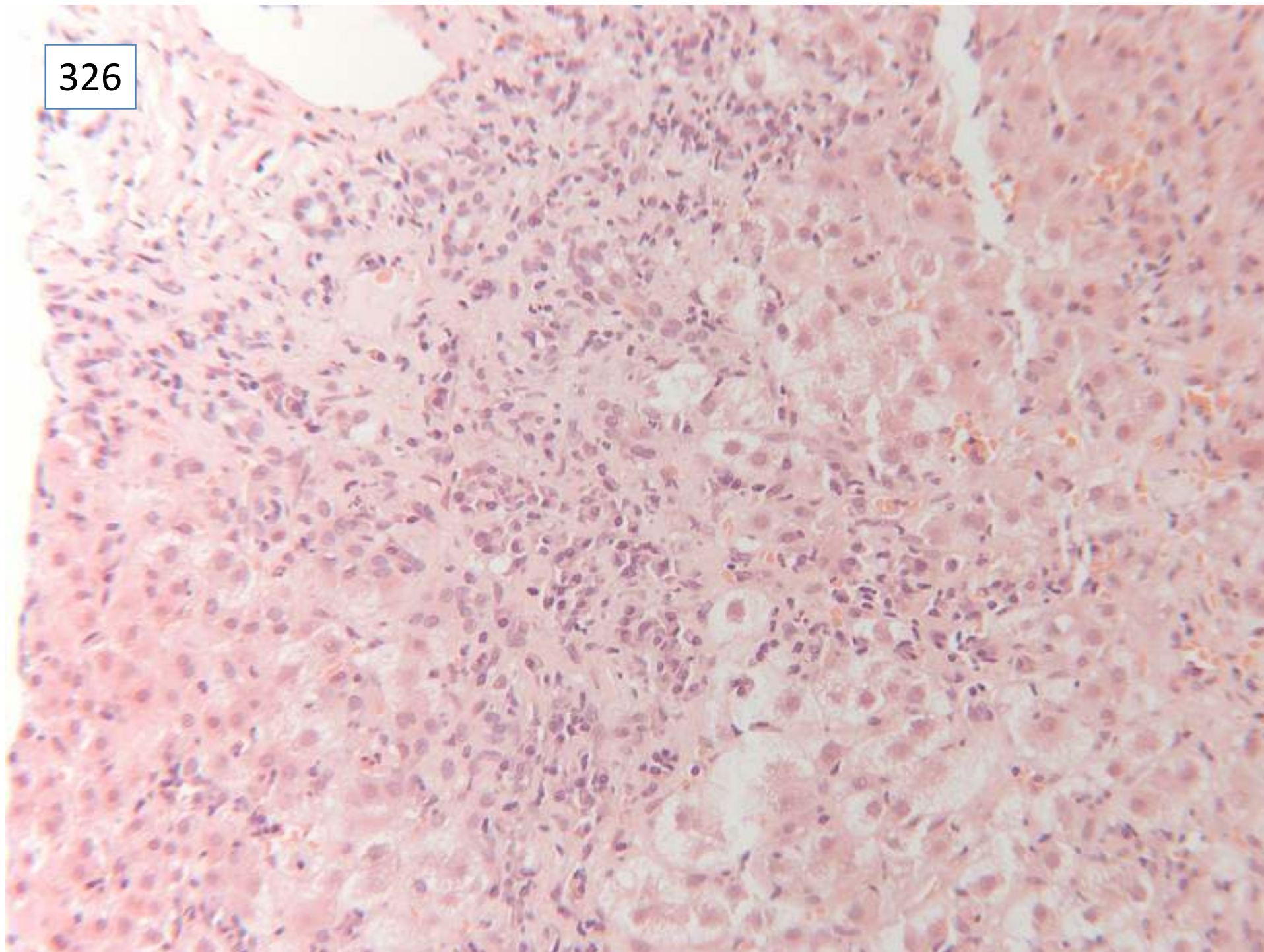
326



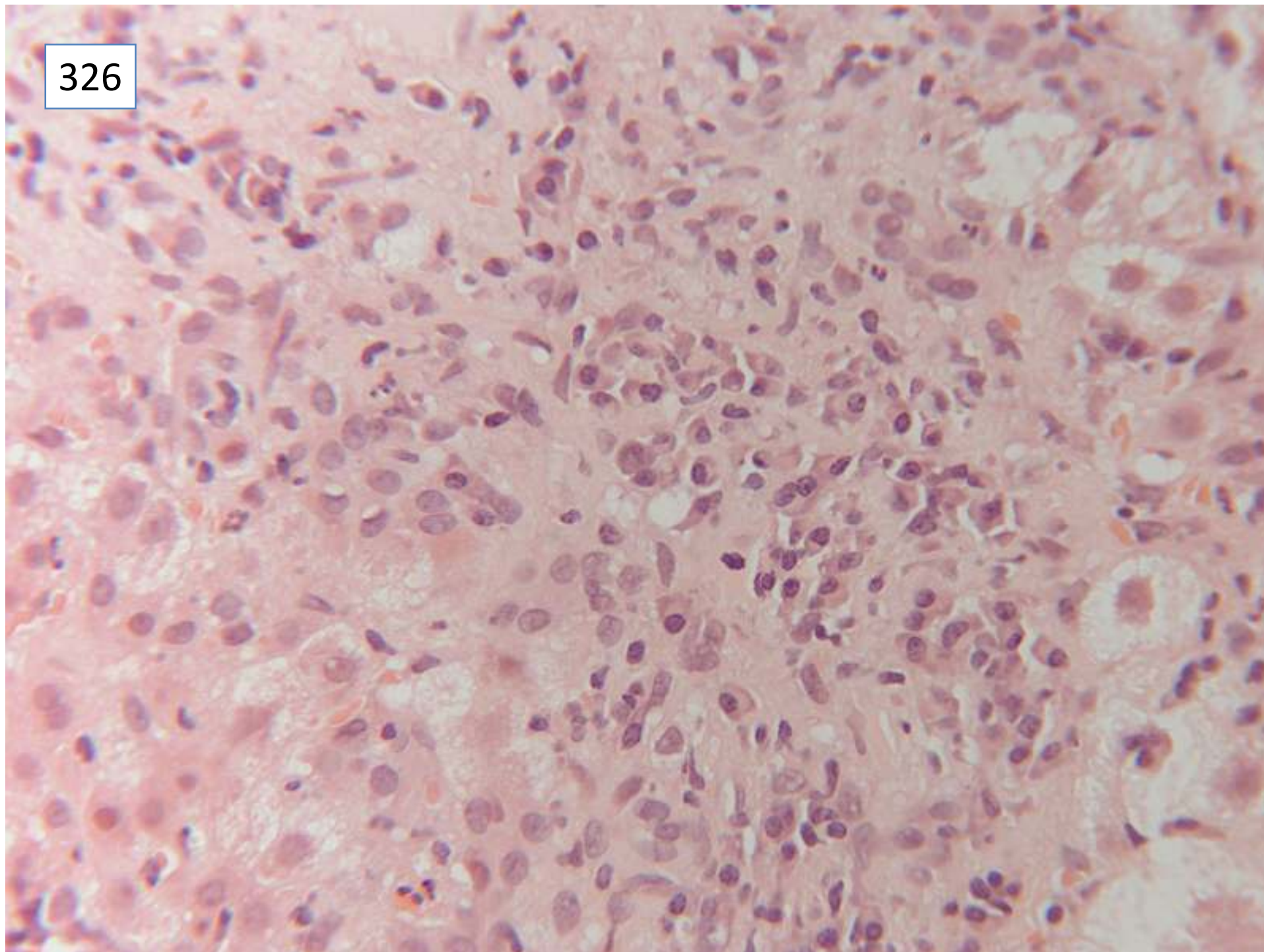
326



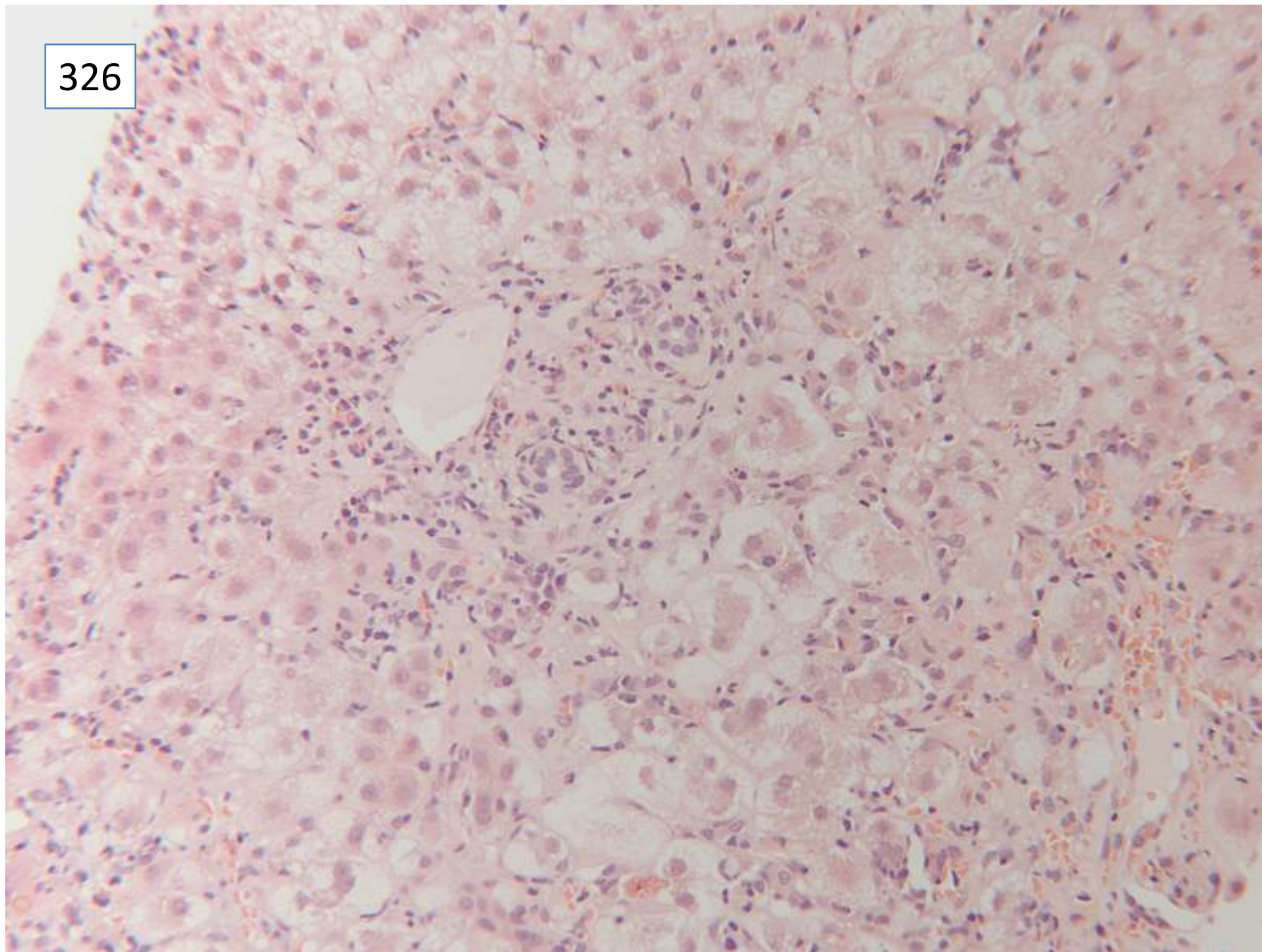
326



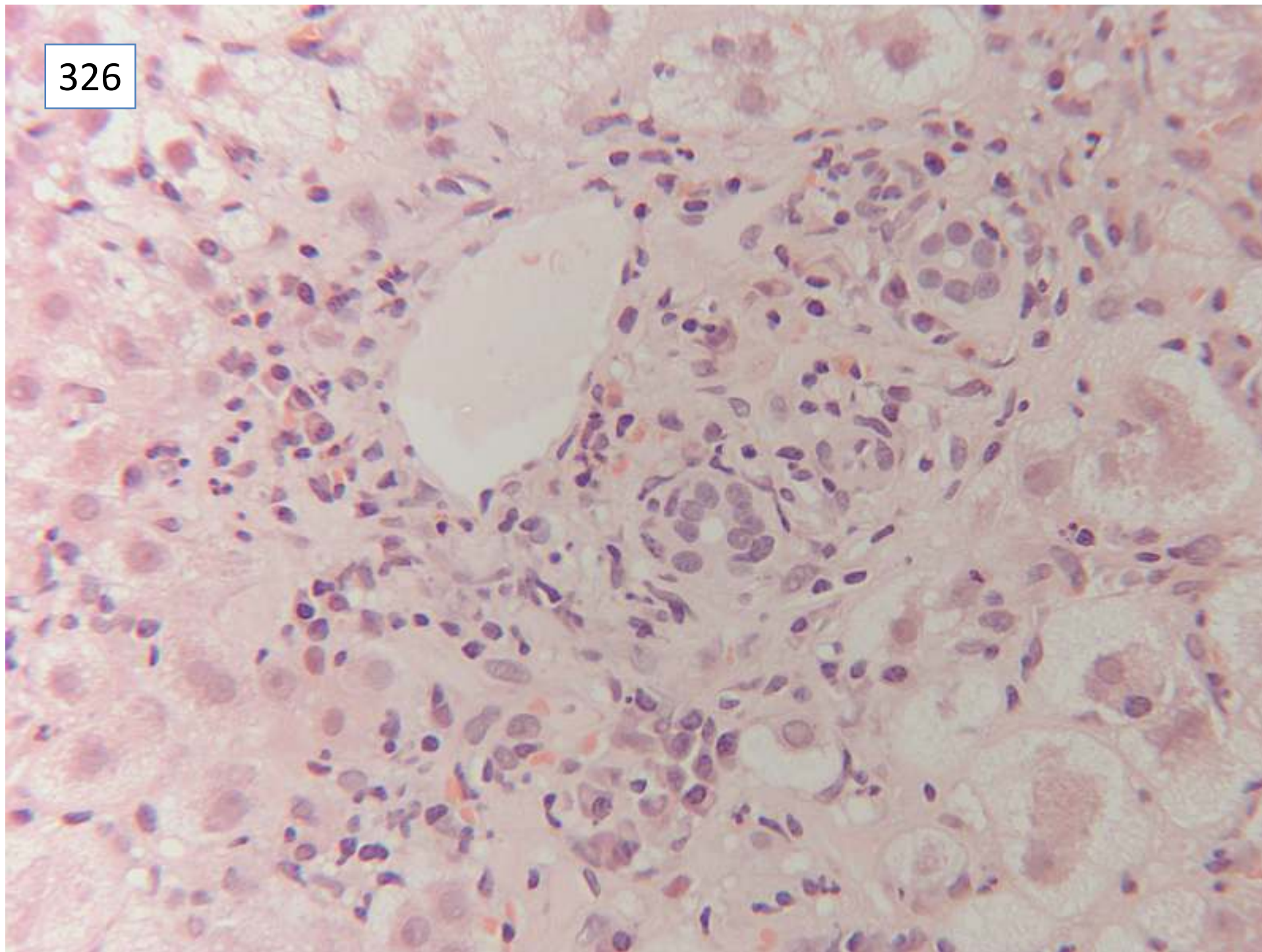
326



326



326



ResponsesMorphology:

- 19 acute hepatitis
- 11 acute hepatitis with bridging or confluent necrosis
- 14 hepatitis
- 7 chronic active hepatitis
- 1 active hepatitis
- 2 *overlap autoimmune hepatitis/cholangitis*
- 1 *hepatitis secondary to SLE (only diagnosis)*
- 1 *autoimmune cholangitis (no mention of hepatitis)*
- 34 any of above with specific mention of prominent plasma cells

Aetiology:

- 19 autoimmune hepatitis with no differential
- 25 autoimmune hepatitis most likely
- 25 differential includes drugs
- 10 differential includes viral hepatitis
- 5 autoimmune hepatitis among differential, not most likely
- 1 *lupoid hepatitis, no differential*
- 1 *no mention of autoimmune hepatitis in differential*

Scoring and discussion.

Score 5 points for any answer including hepatitis except as indicated above. This case showed confluent bridging necrosis which is an important indicator of severity and should be included in the report. Chronicity requires connective tissue stains for accurate evaluation, so points were not deducted for diagnoses of chronic disease, although the consensus for this case was of acute disease. There were no histological or clinical features to suggest overlap with biliary disease. Hepatitis is rarely a component of the multisystem disease of SLE, and the serology given does not point to SLE.

Prominent plasma cells are an important feature contributing to the overall clinical diagnosis of autoimmune hepatitis and should be included in the report, but was not included in the EQA scoring.

Aetiology: 5 points deducted for failure to include autoimmune in the diagnosis; lupoid hepatitis is an old terminology, and may be misleading – the current terminology is for a diagnosis of autoimmune hepatitis with additional comment on severity of necrosis, interface activity and chronicity.

Submitting pathologist's diagnosis:

Autoimmune hepatitis with bridging fibrosis

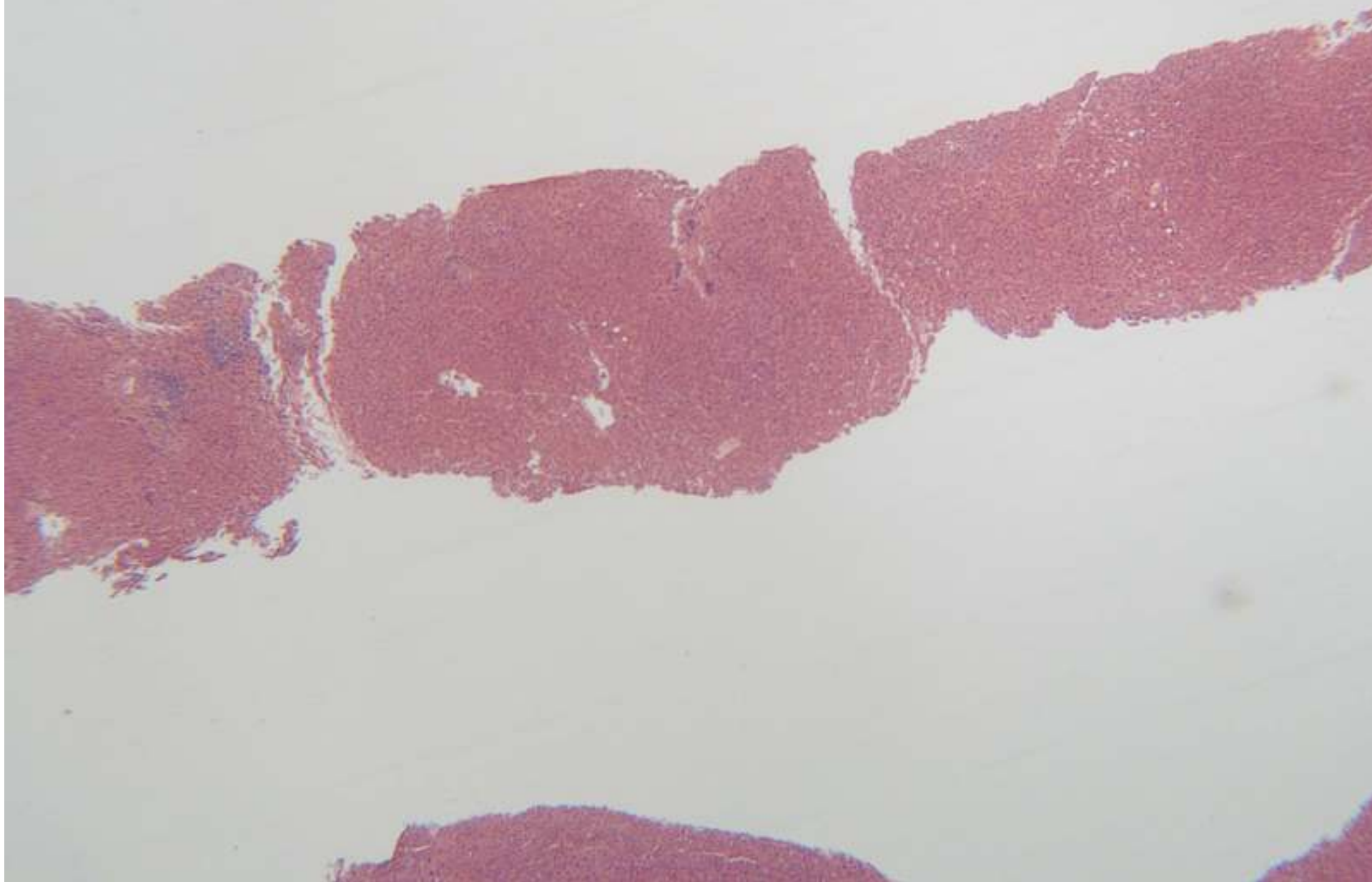
Follow up: after the biopsy the patient received prednisolone and azathioprine, and the LFTs returned to normal, confirming the diagnosis of autoimmune hepatitis.

Case 327

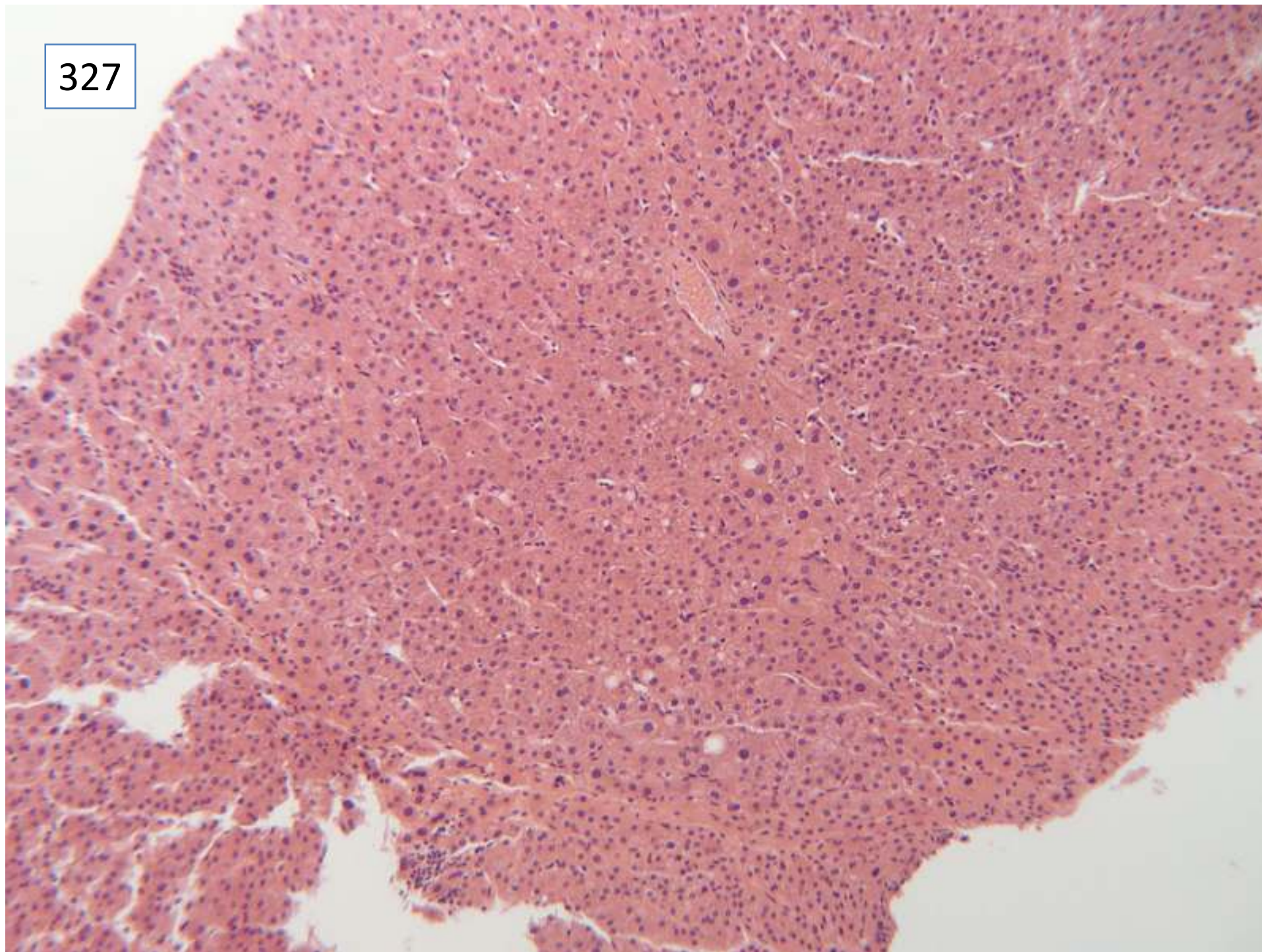
Female 61 years

Unexpected cirrhosis at lap chole

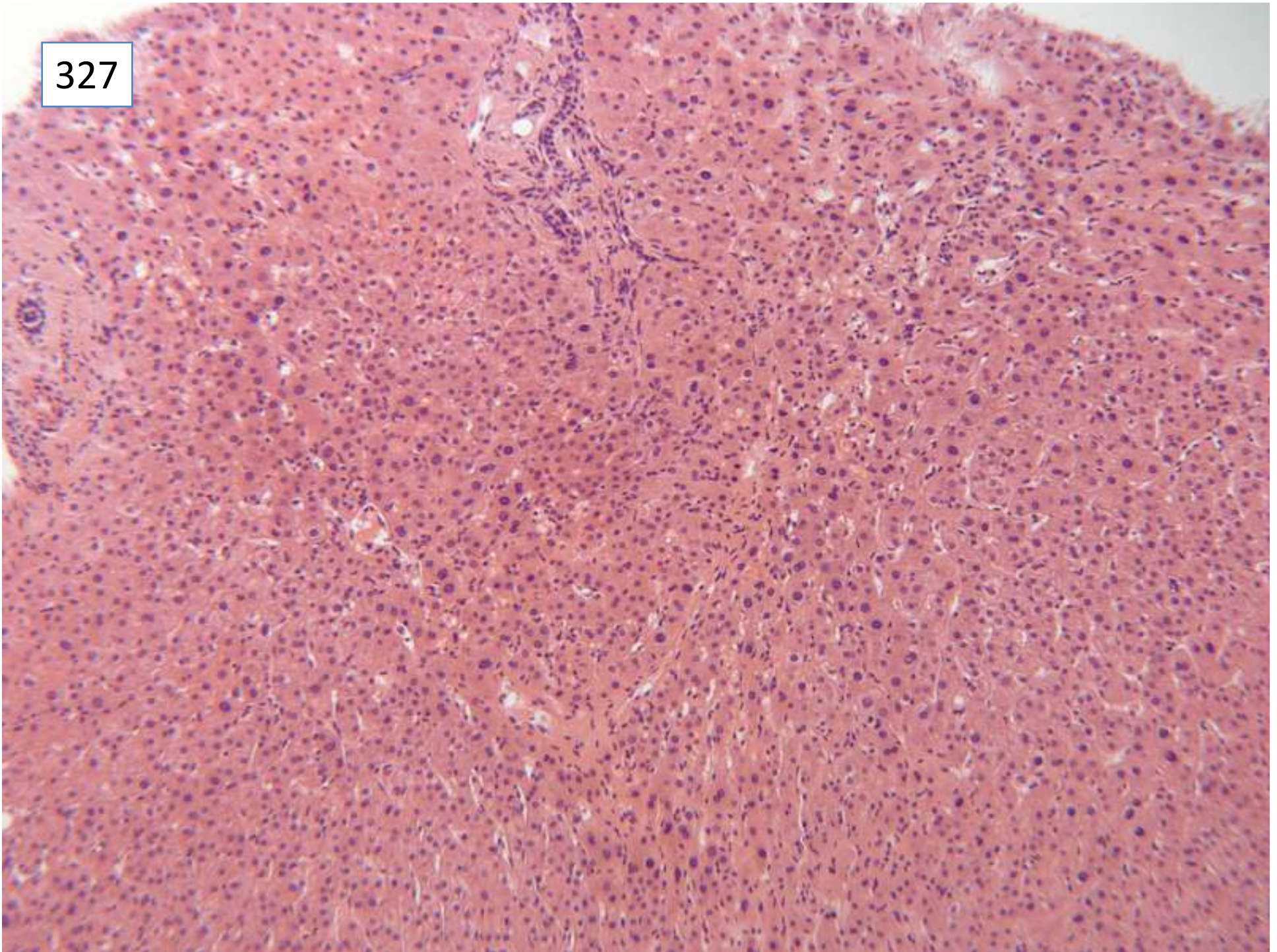
327



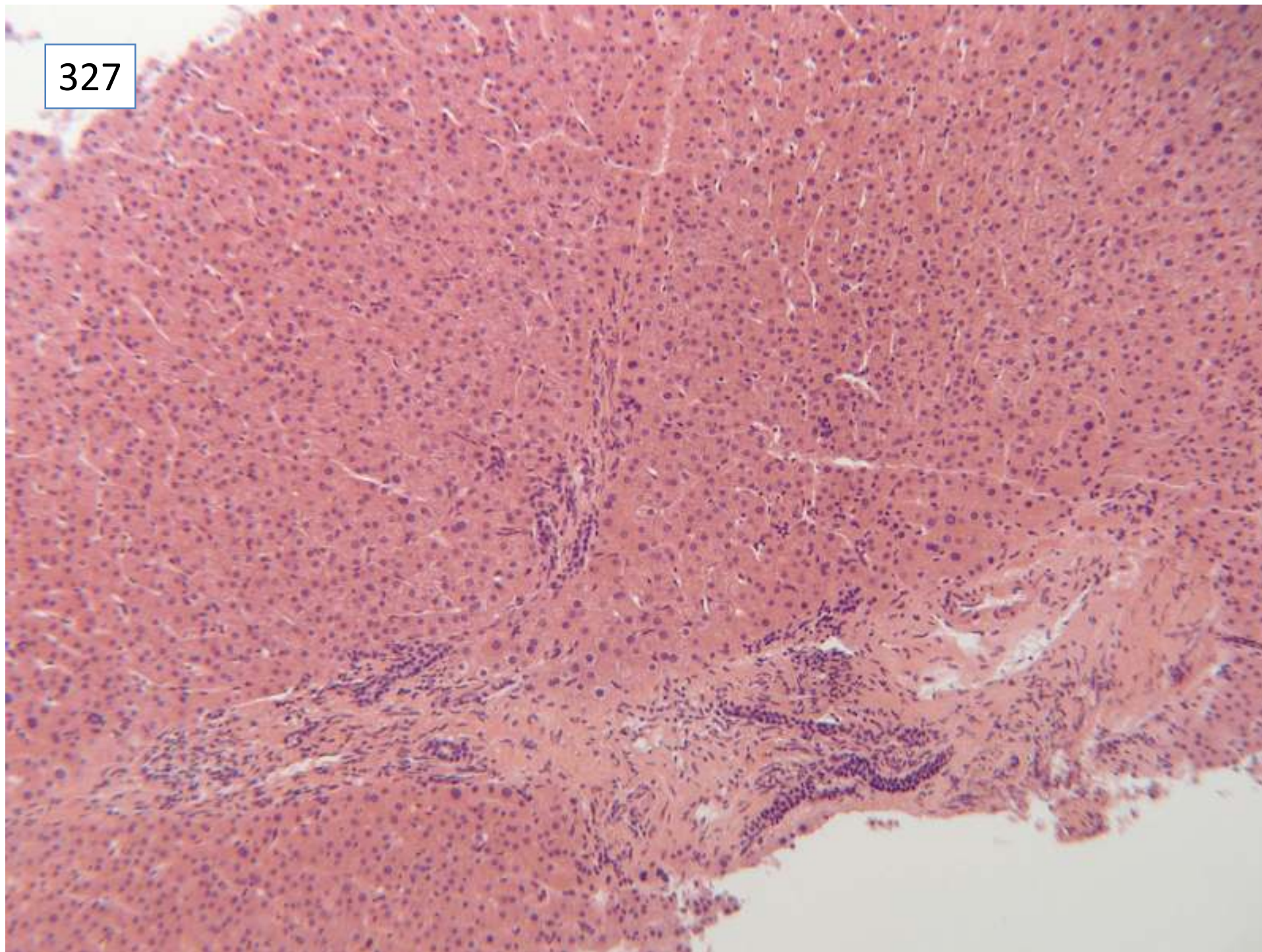
327



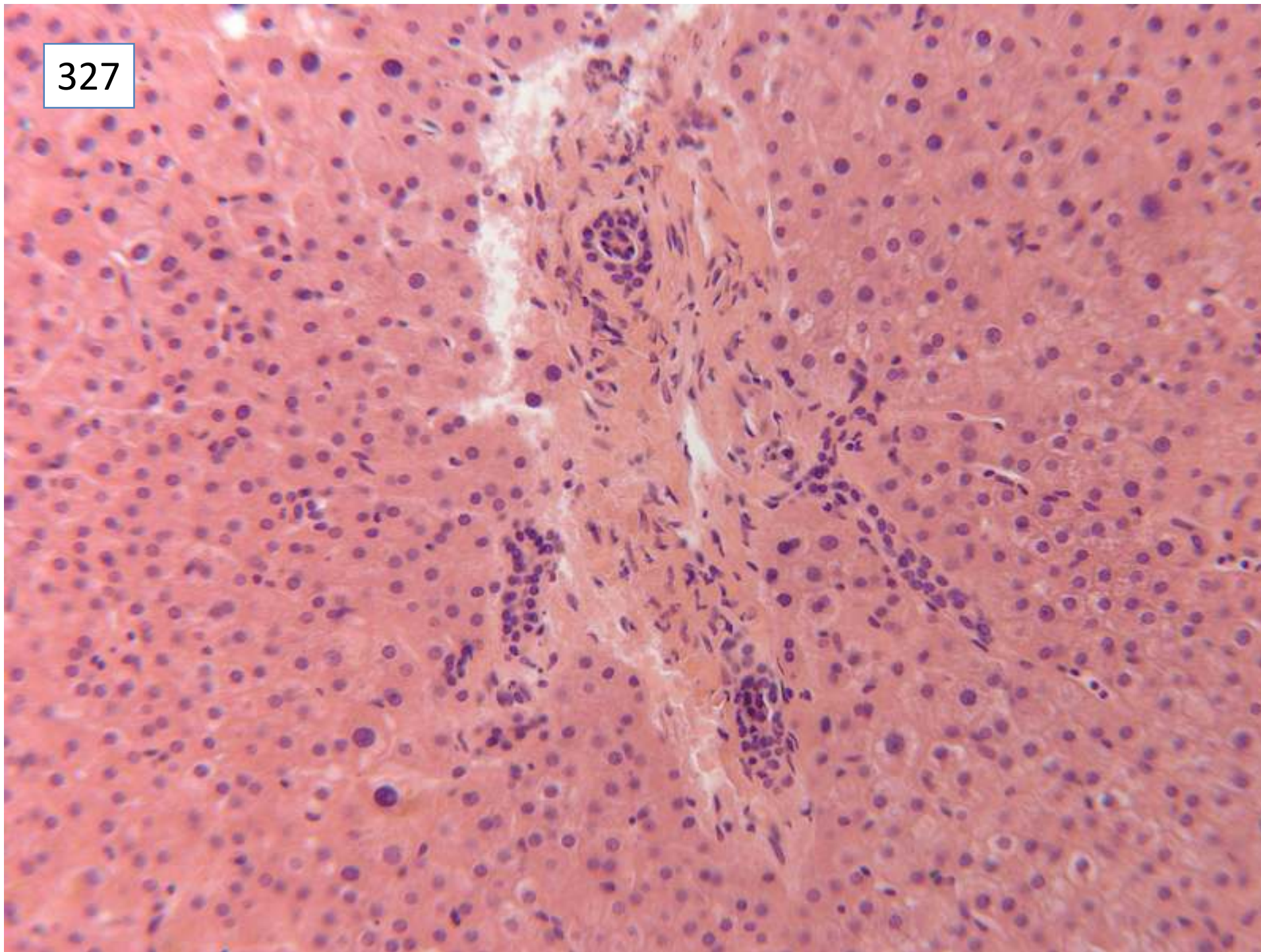
327



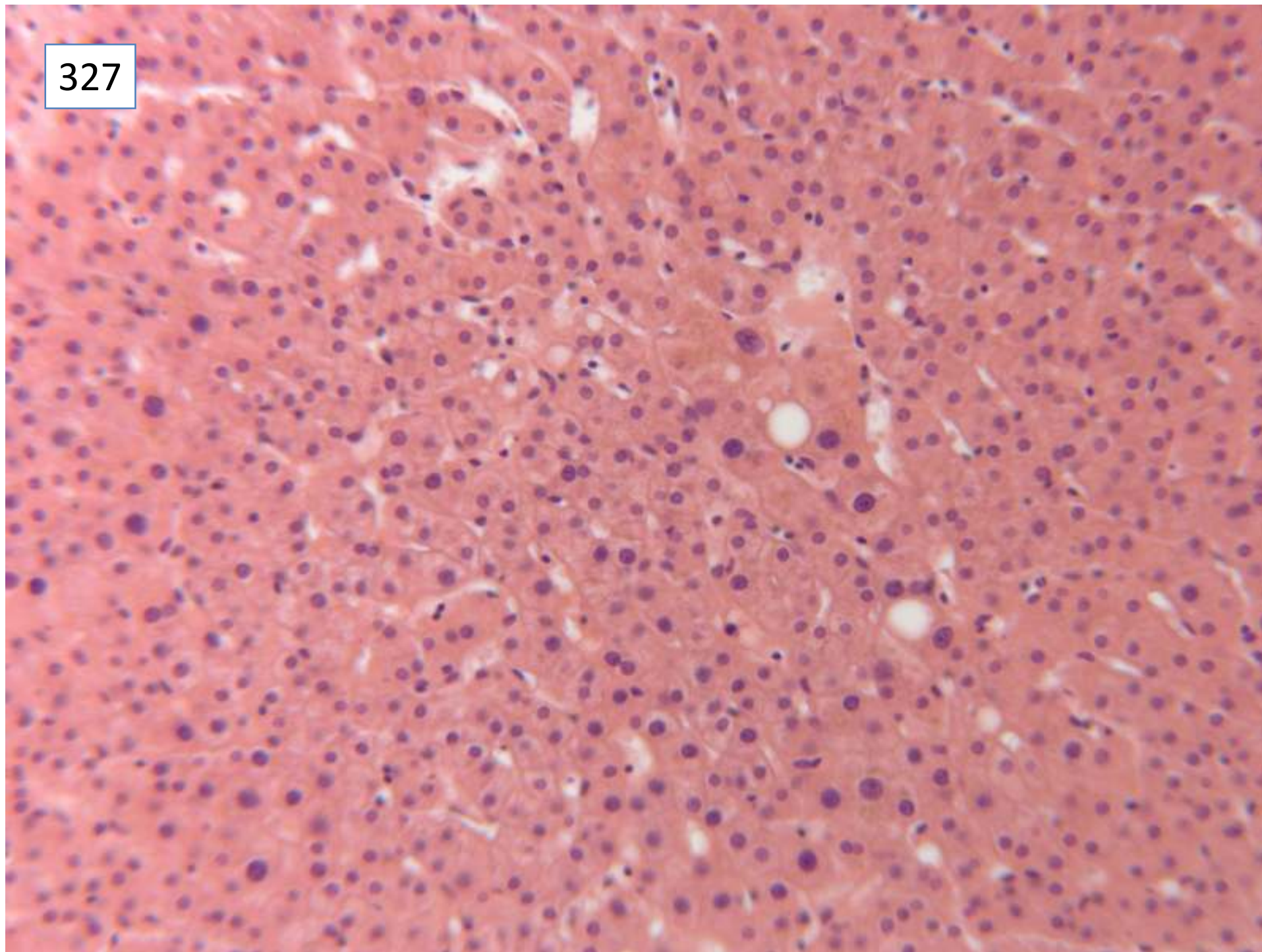
327



327



327



Responses

- 16 nodular regenerative hyperplasia as definite diagnosis
- 11 possible nodular regenerative hyperplasia
- 3 possible or definite cirrhosis, as morphological diagnosis
- 4 cirrhosis, likely clinical diagnosis despite not being confirmed by this biopsy
- 11 non-diagnostic biopsy, needs special stains
- 4 chronic biliary disease/obstruction
- 1 primary biliary cirrhosis
- 1 hepatoportal sclerosis
- 1 hyperplastic nodular process
- 1 no specific abnormality, fatty change only
- 1 lipogranulomas (as main diagnosis)
- 1 amyloid
- 2 iron overload and mild steatosis

Case not scored

Scoring and discussion:

This case had insufficient consensus for scoring.

The submitted and most popular diagnosis was nodular regenerative hyperplasia. It was commented that macronodular cirrhosis could not be completely excluded by needle biopsy, and more clinico-pathological correlation was required to reach a diagnosis in this case.

Submitting pathologist's diagnosis:

Nodular regenerative hyperplasia

Case 328

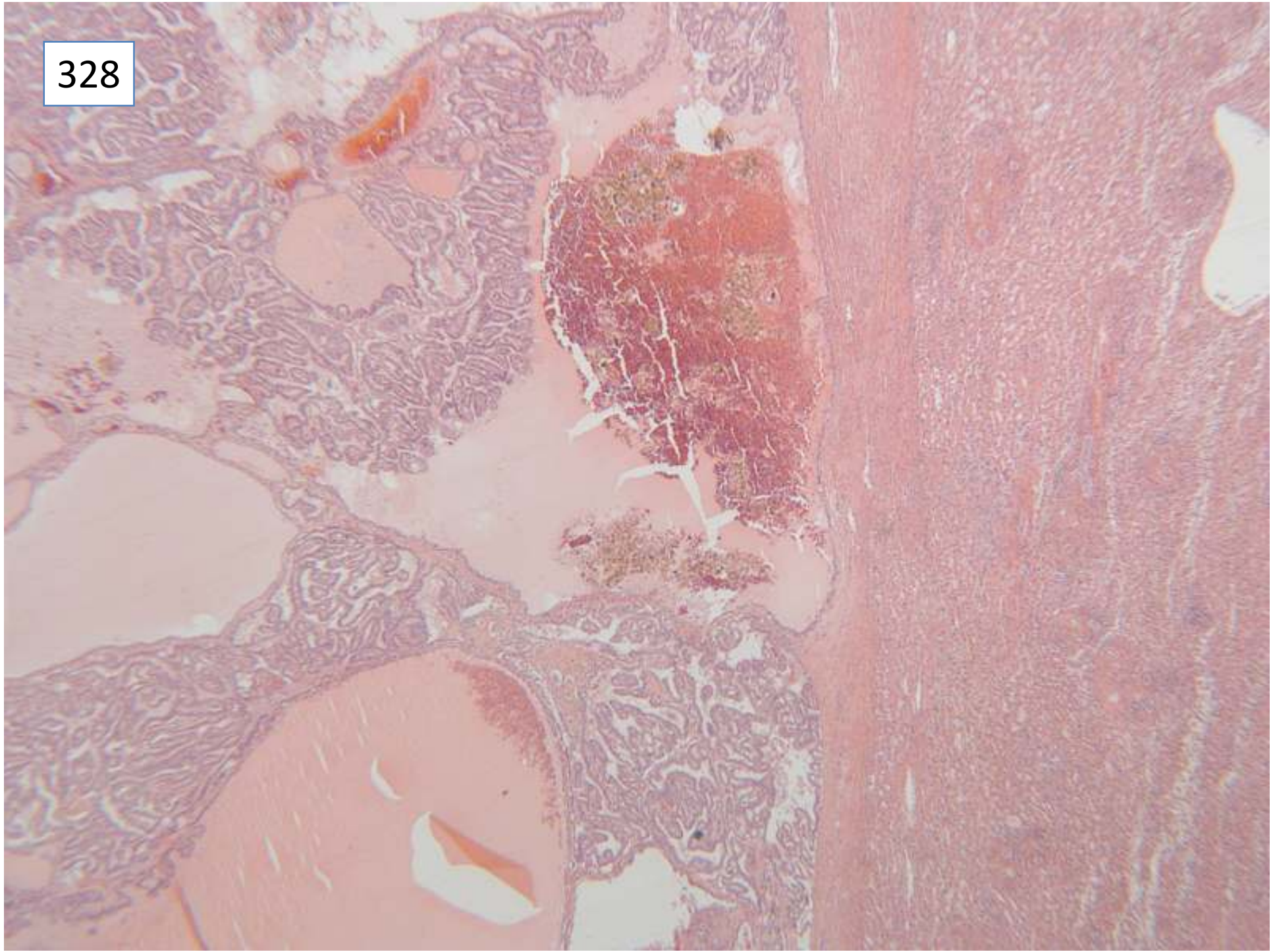
Female 53 years

Lateral left liver lobe cyst ?cystadenoma

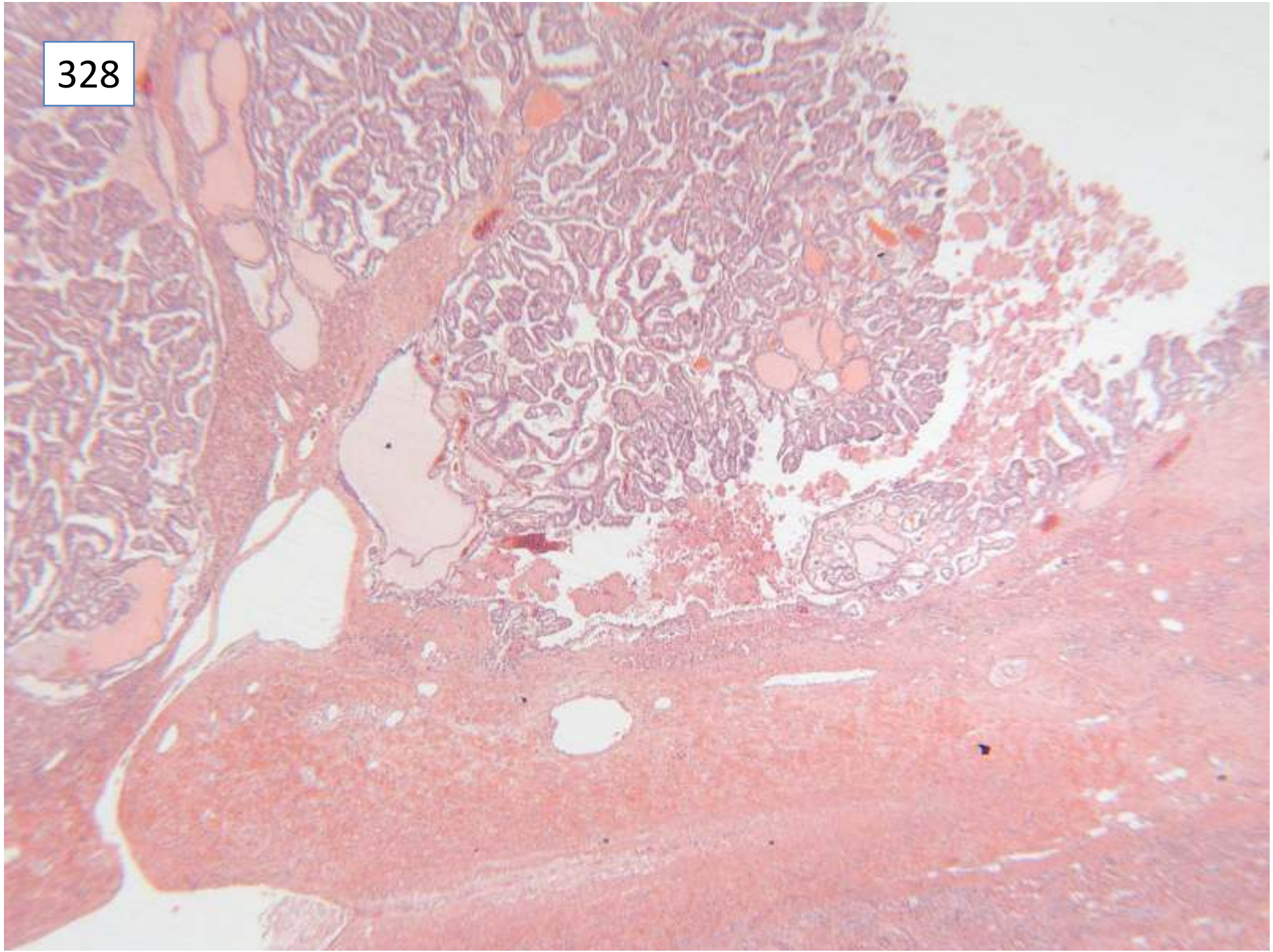
Specimen: Lateral liver lobectomy

Macroscopic description: Partial hepatectomy containing a unilocular cyst 100X85mm in which abundant red/brown material is present. Background liver looks normal.

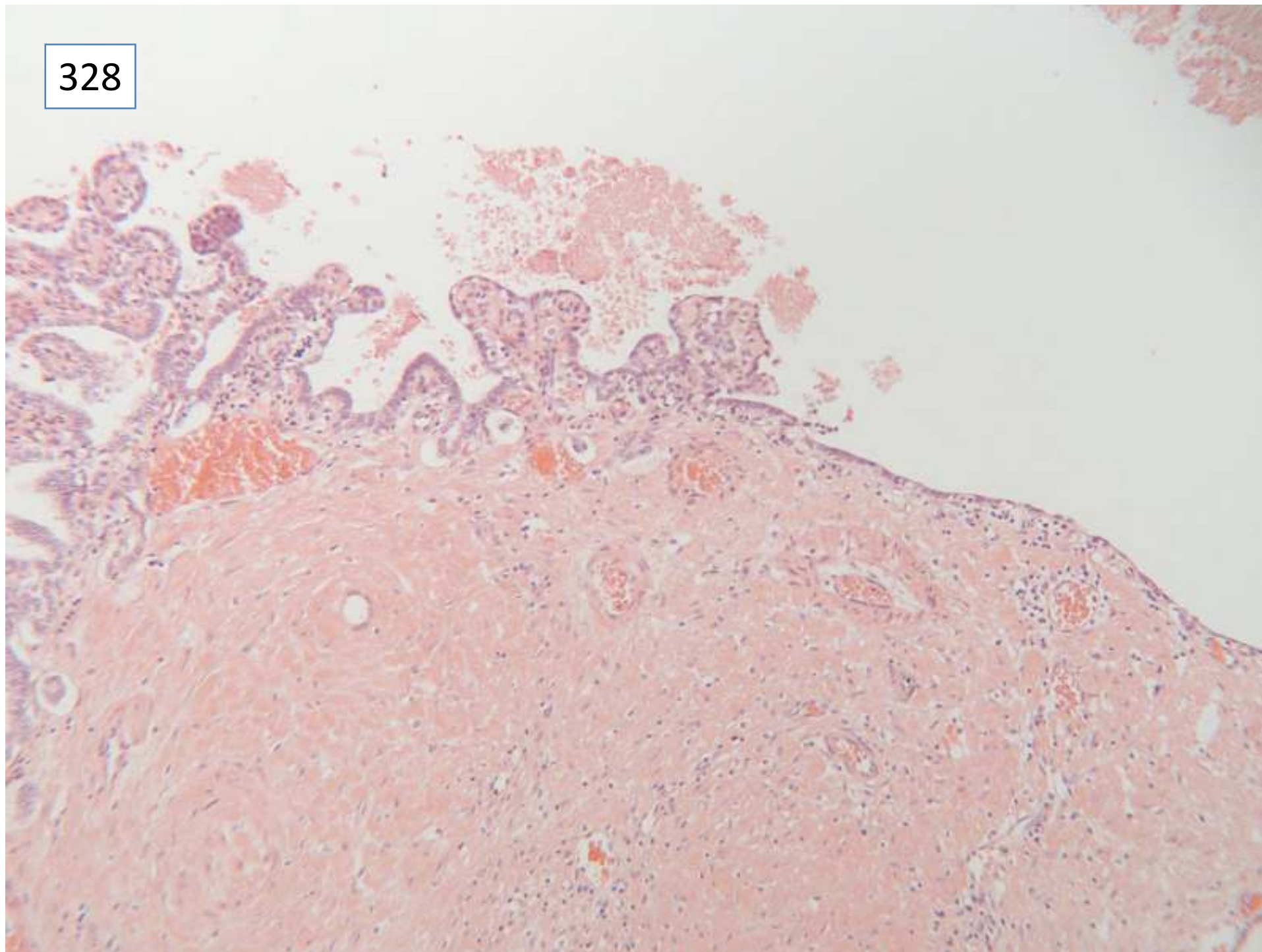
328



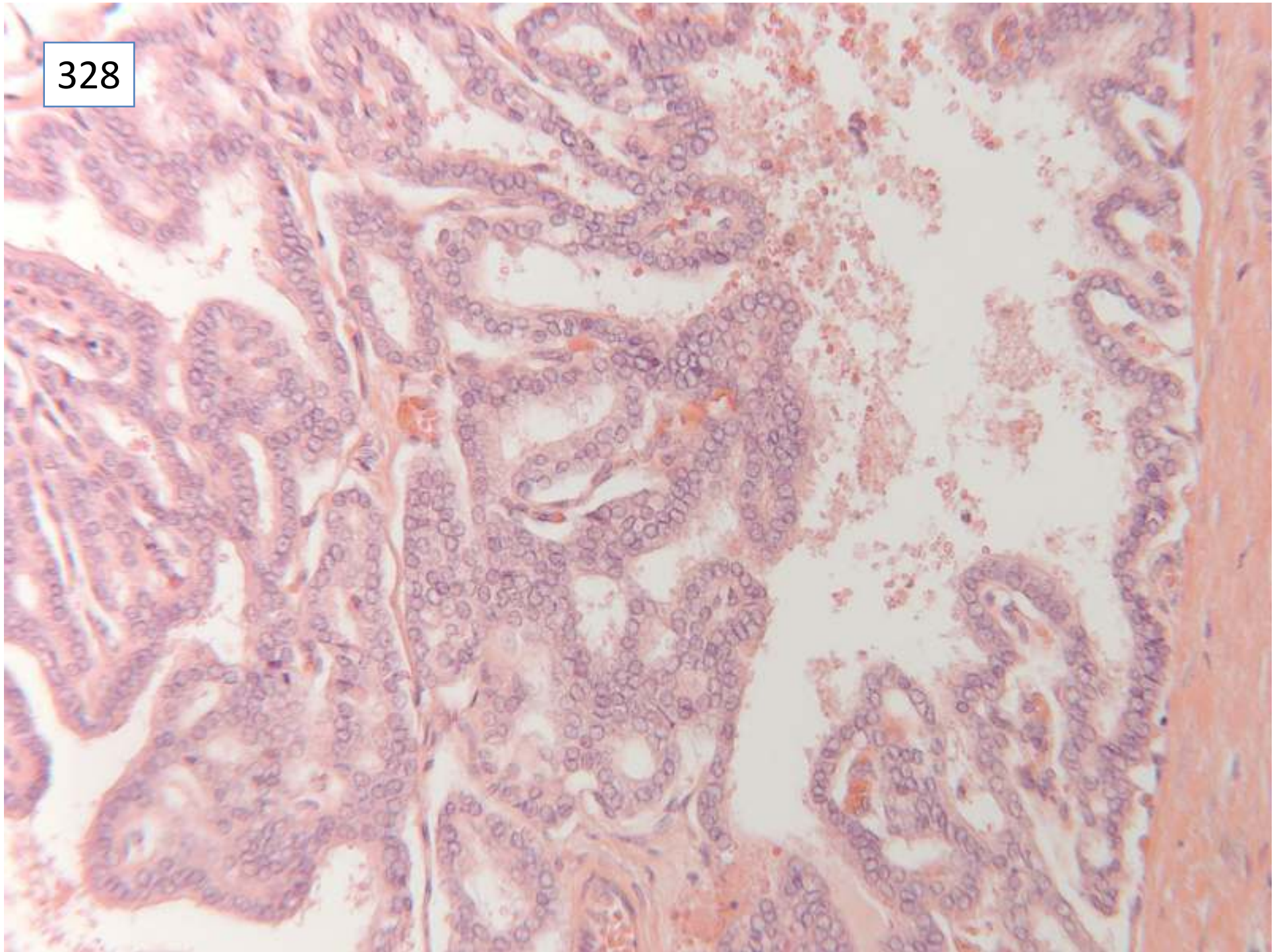
328



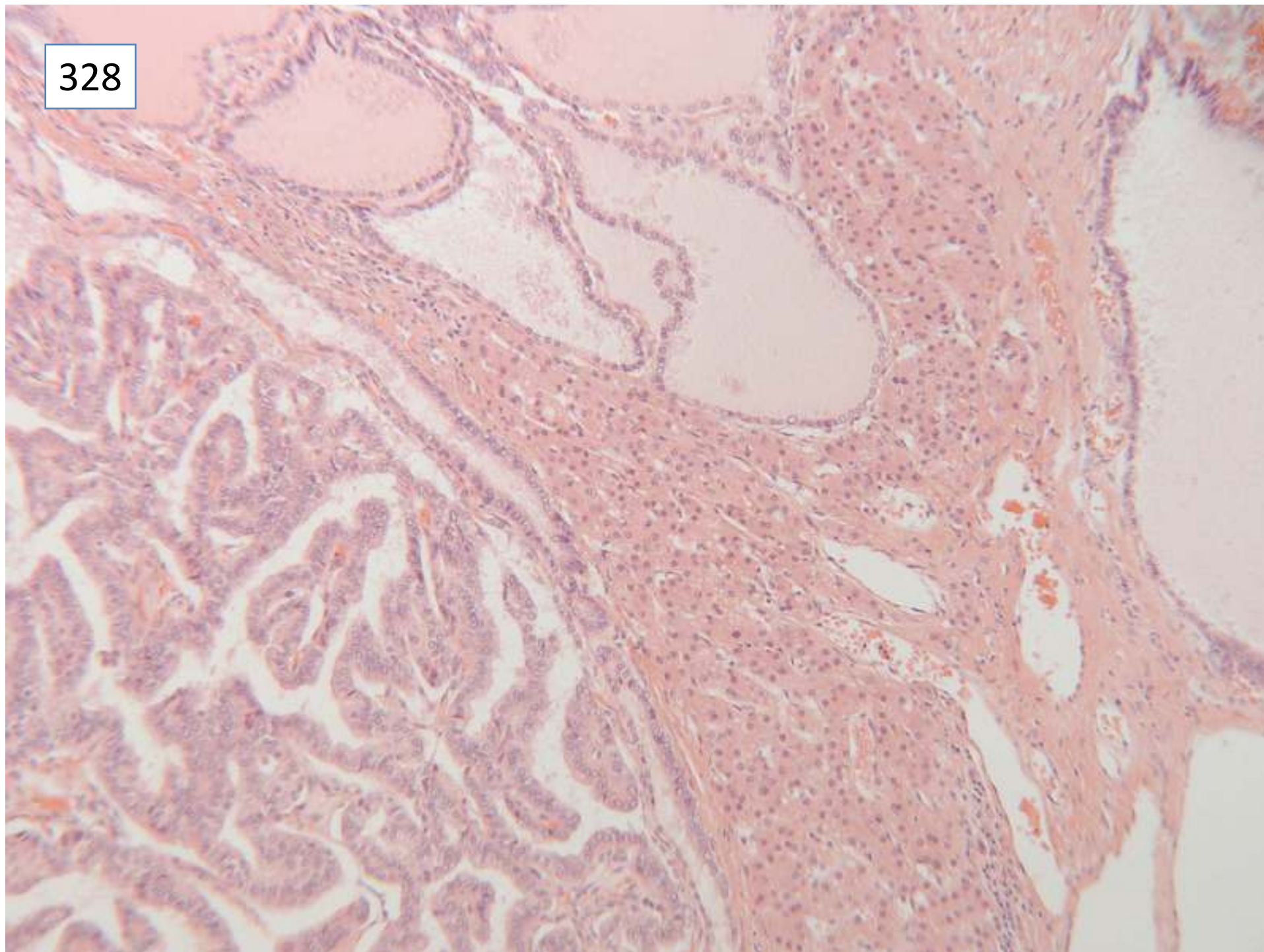
328



328



328



Responses

14 primary biliary cystic tumour, no differential diagnosis

17 biliary cystic tumour, differential diagnosis including metastatic thyroid carcinoma

4 metastatic thyroid carcinoma with differential diagnosis

1 metastatic papillary carcinoma, differential pancreas, kidney, lung, thyroid

14 metastatic thyroid carcinoma, no differential given but immunohistochemistry requested

5 metastatic thyroid carcinoma, no immunos.

Scoring and discussion

Discussion over whether there was sufficient consensus to include scoring on this case. Members voted to accept diagnoses that included the possibility of metastatic carcinoma. The clear, overlapping nuclei of the papillary tumour were very characteristic of papillary thyroid carcinoma.

Further information from submitting pathologist – this patient had a thyroid FNA showing papillary carcinoma two weeks before this surgery – there was a lack of communication of this result between clinical teams. The tumour is immunohistochemically positive for TTF.

Submitting pathologist's diagnosis: metastatic papillary carcinoma of the thyroid

Case 329

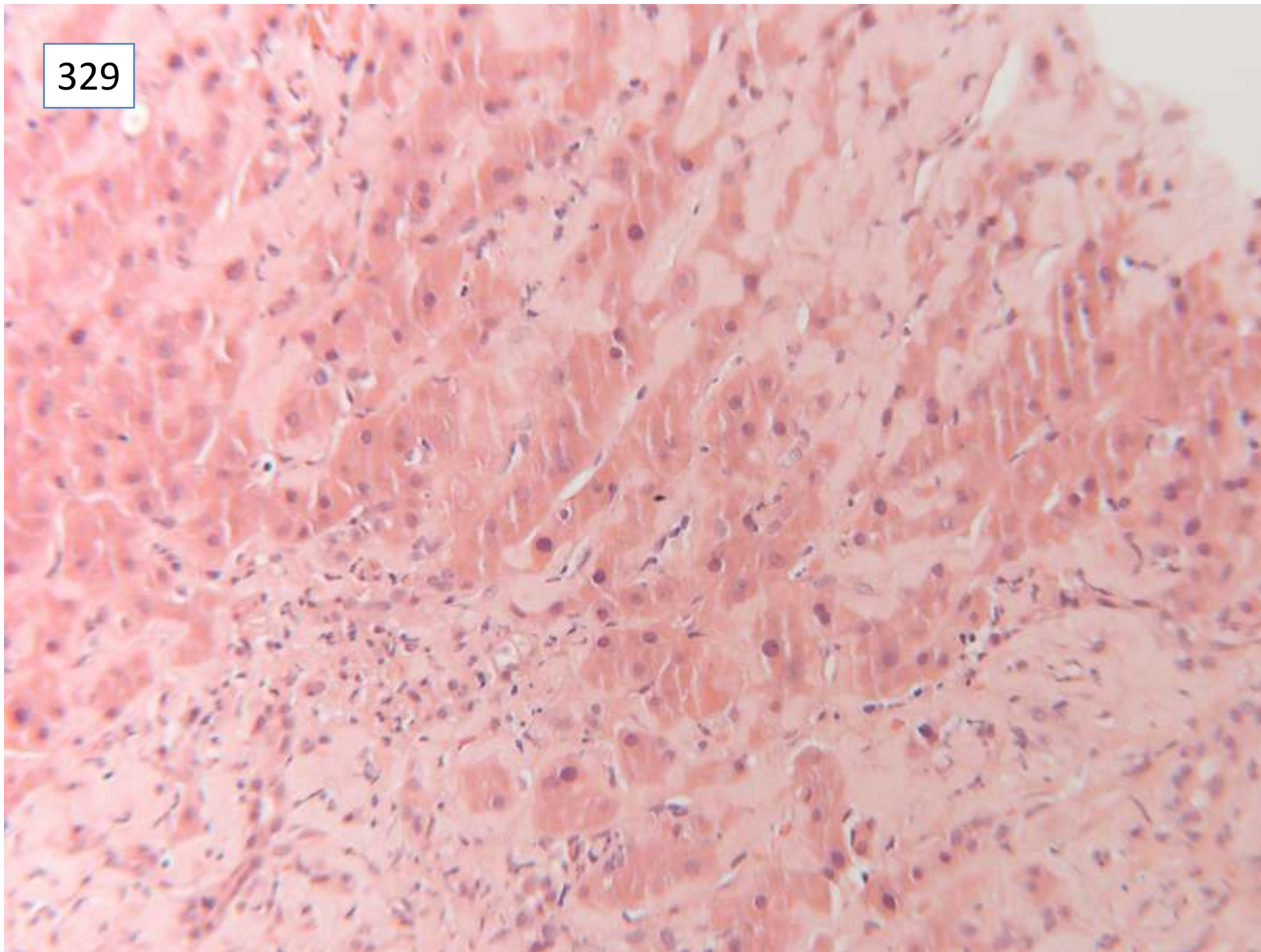
Female 79 years

Presented with cholestatic liver function tests with an ALP of 319. Known to have congestive cardiac failure. Liver screen normal. Not obese. CT scan showed no evidence of biliary dilation

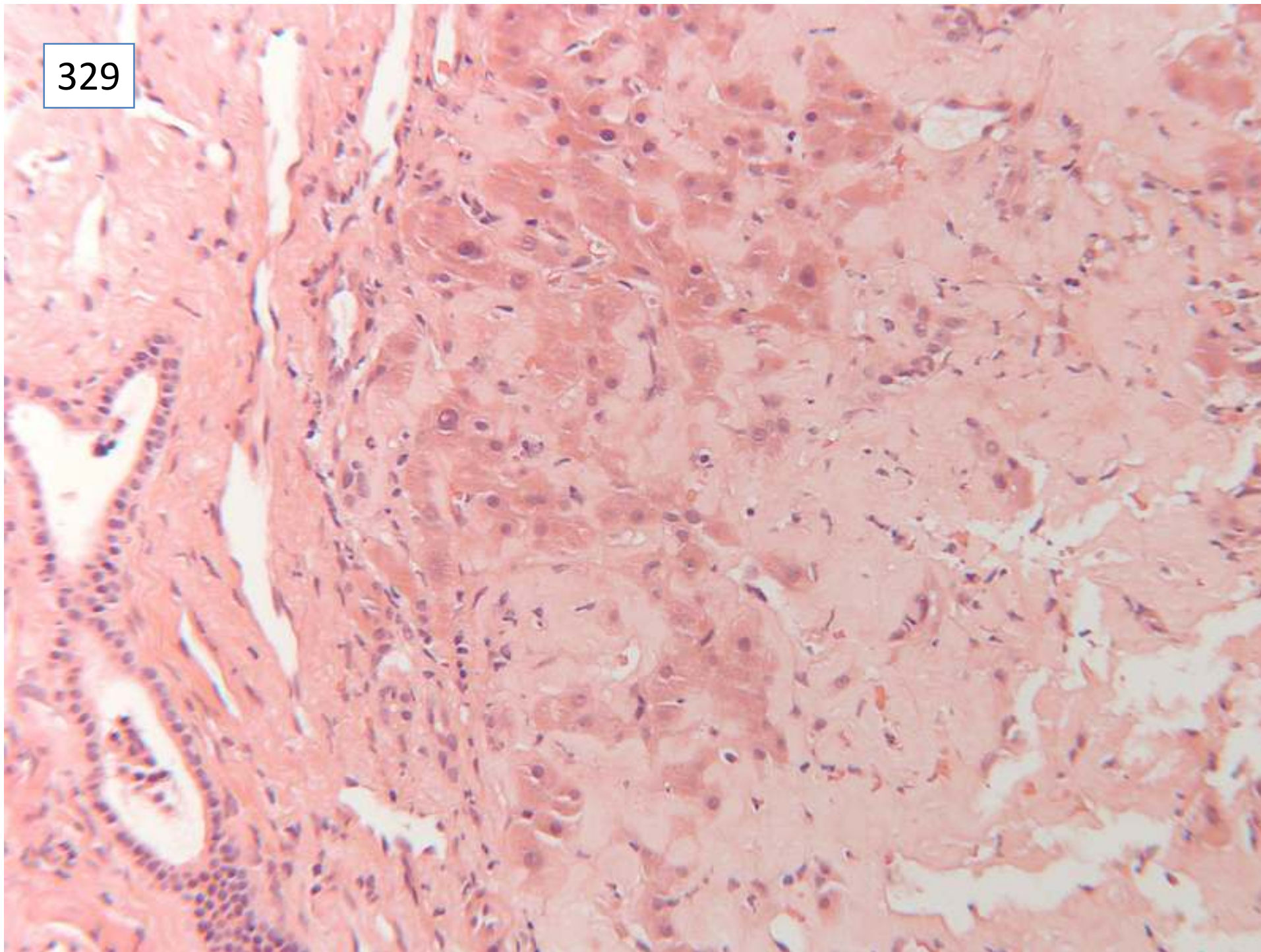
329



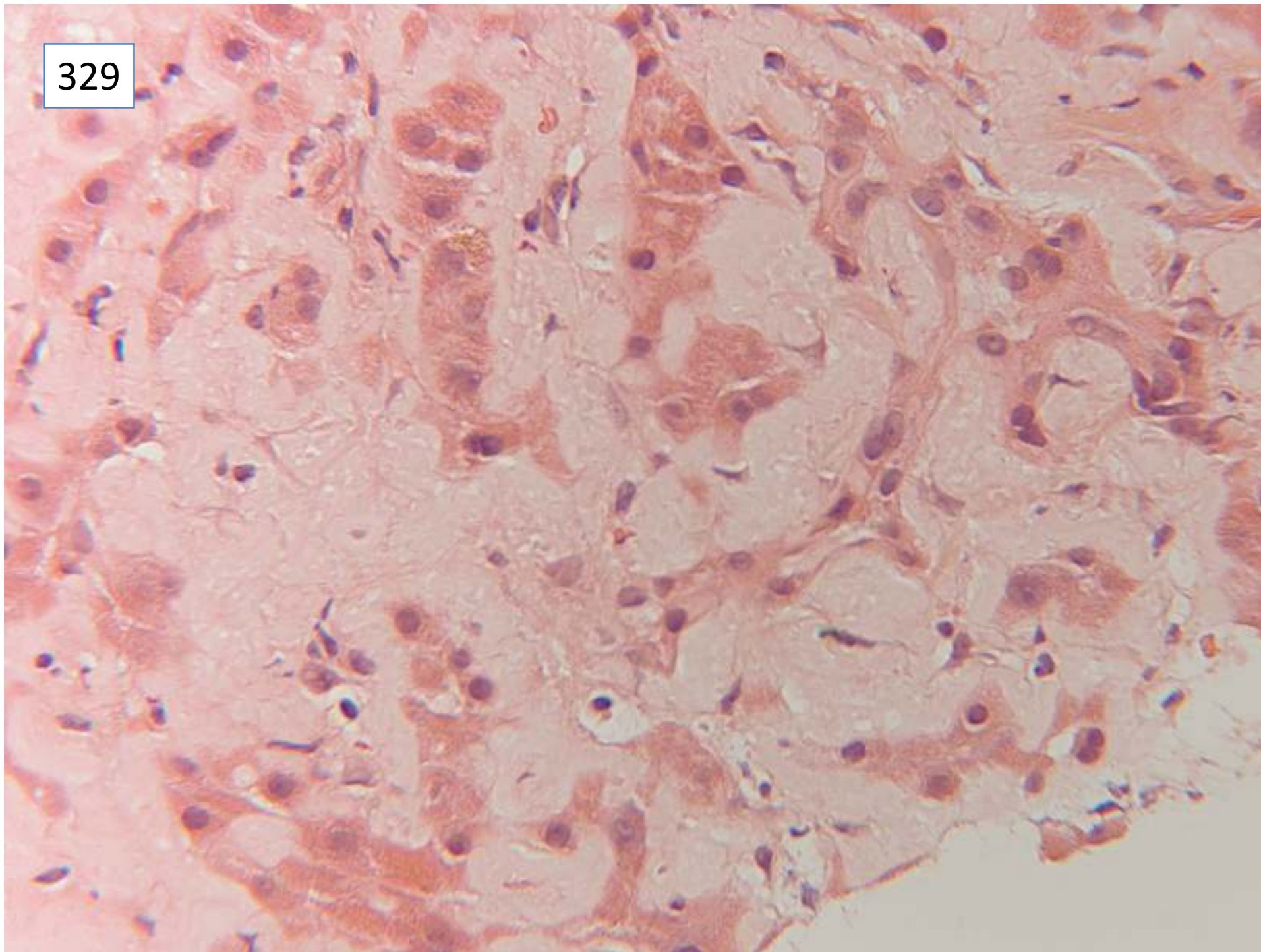
329



329



329



Responses

- 30 amyloid, includes clinical comment about need for investigation of cause
- 21 amyloid, no comment about clinical investigation
 - 2 amyloid or light chain disease
 - 1 cardiac cirrhosis, need to exclude amyloid, do congo red
 - 1 pseudo-amyloidosis ? cause, not typical of cardiac cirrhosis or amyloid.

Comment: several suggested cardiac failure may be due to cardiac amyloid

Several commented on bilirubinostasis.

Scoring and discussion

All responses scored 10.

Congo red confirmed the diagnosis of amyloid. There is no indication of the type – immunohistochemistry for kappa and lamda both positive. The patient did not survive long. The possibility of cardiac involvement by amyloidosis was raised at the time, but was not further investigated.

Submitting pathologist's diagnosis: hepatic amyloidosis

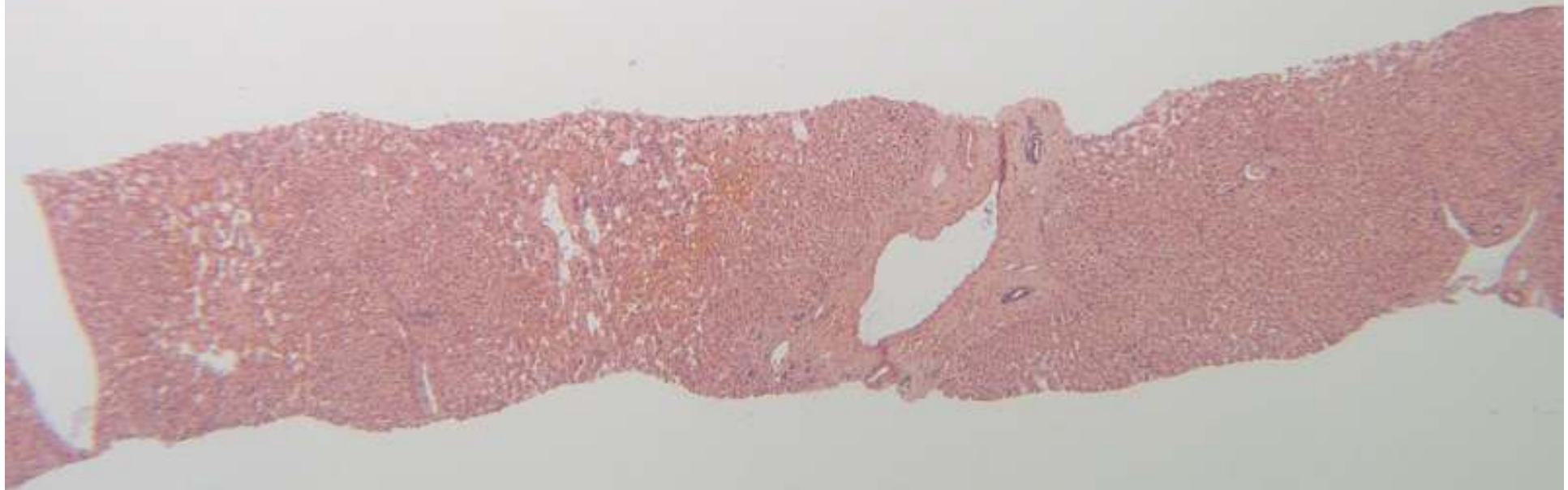
Case 330

Female 47 years

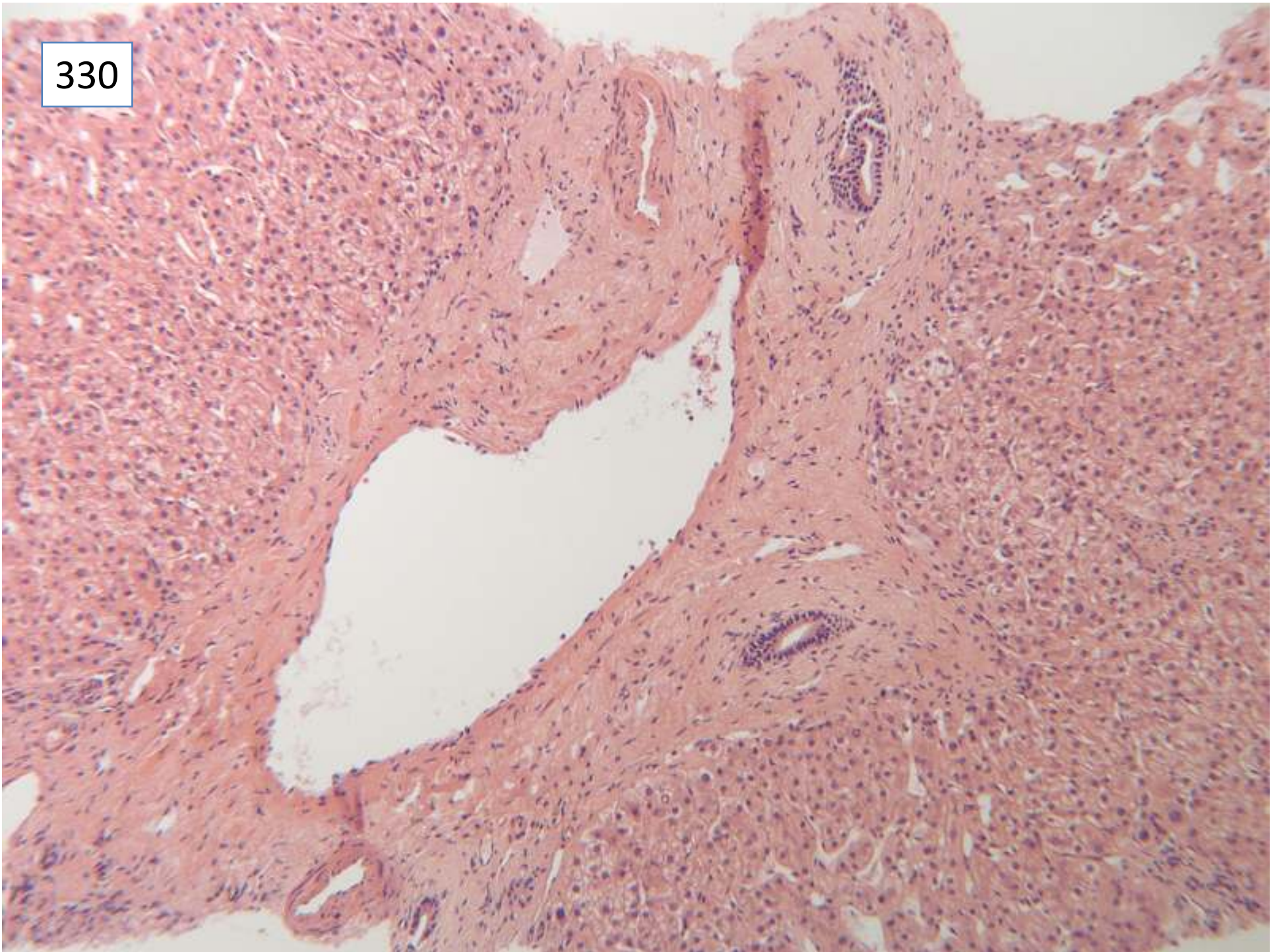
Known ulcerative colitis, elevated alk phos.

?PSC/other pathology

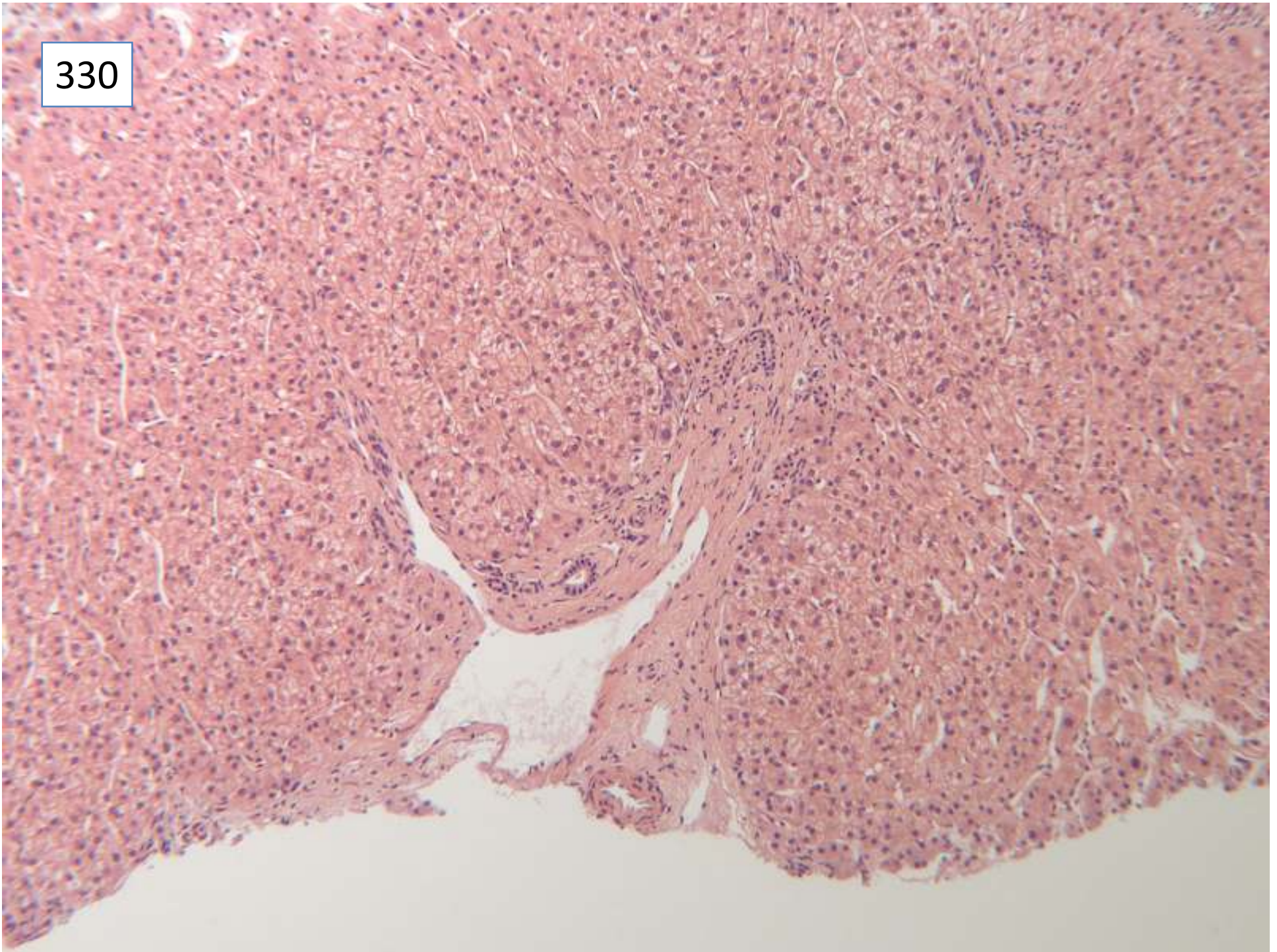
330



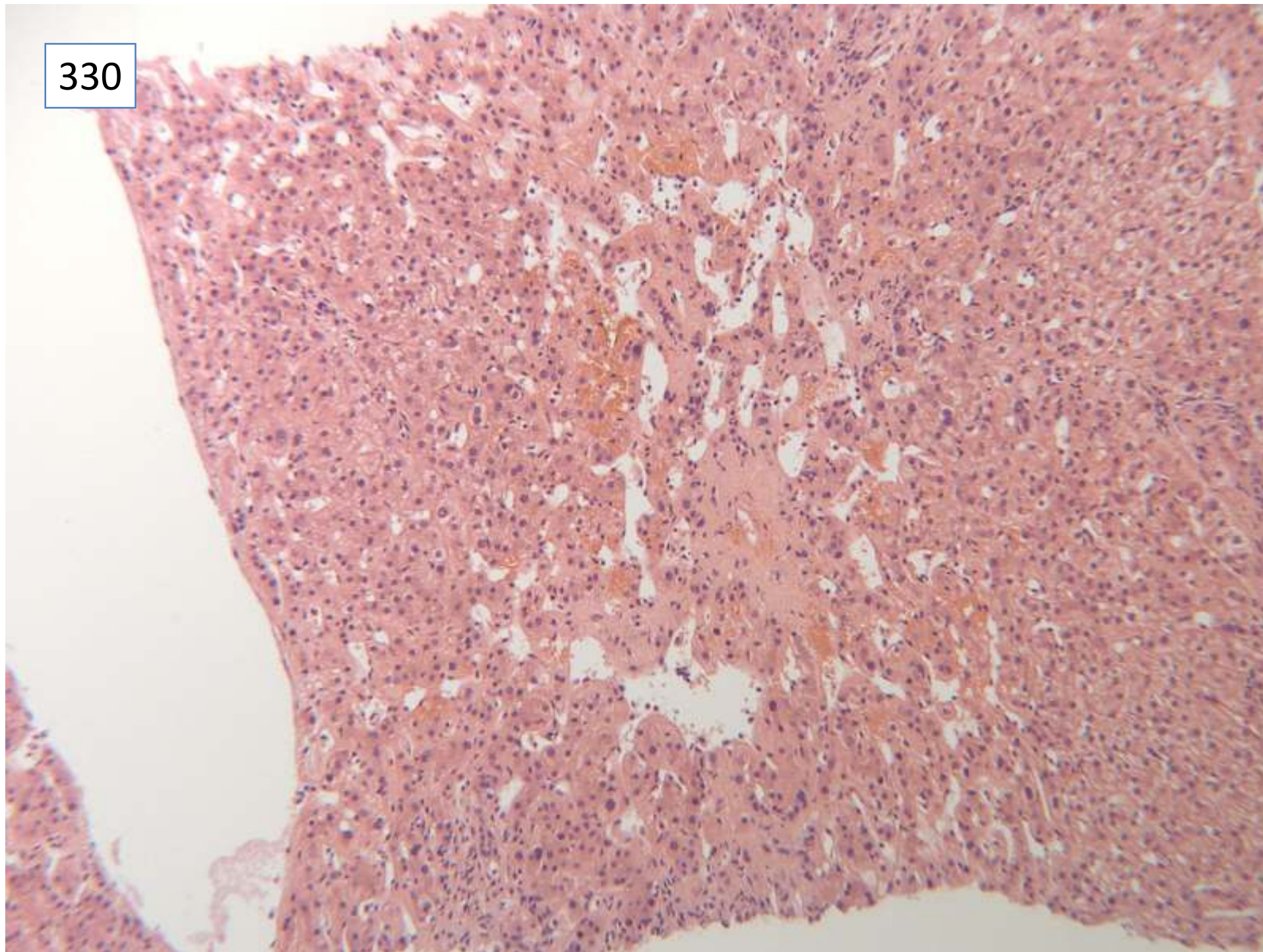
330



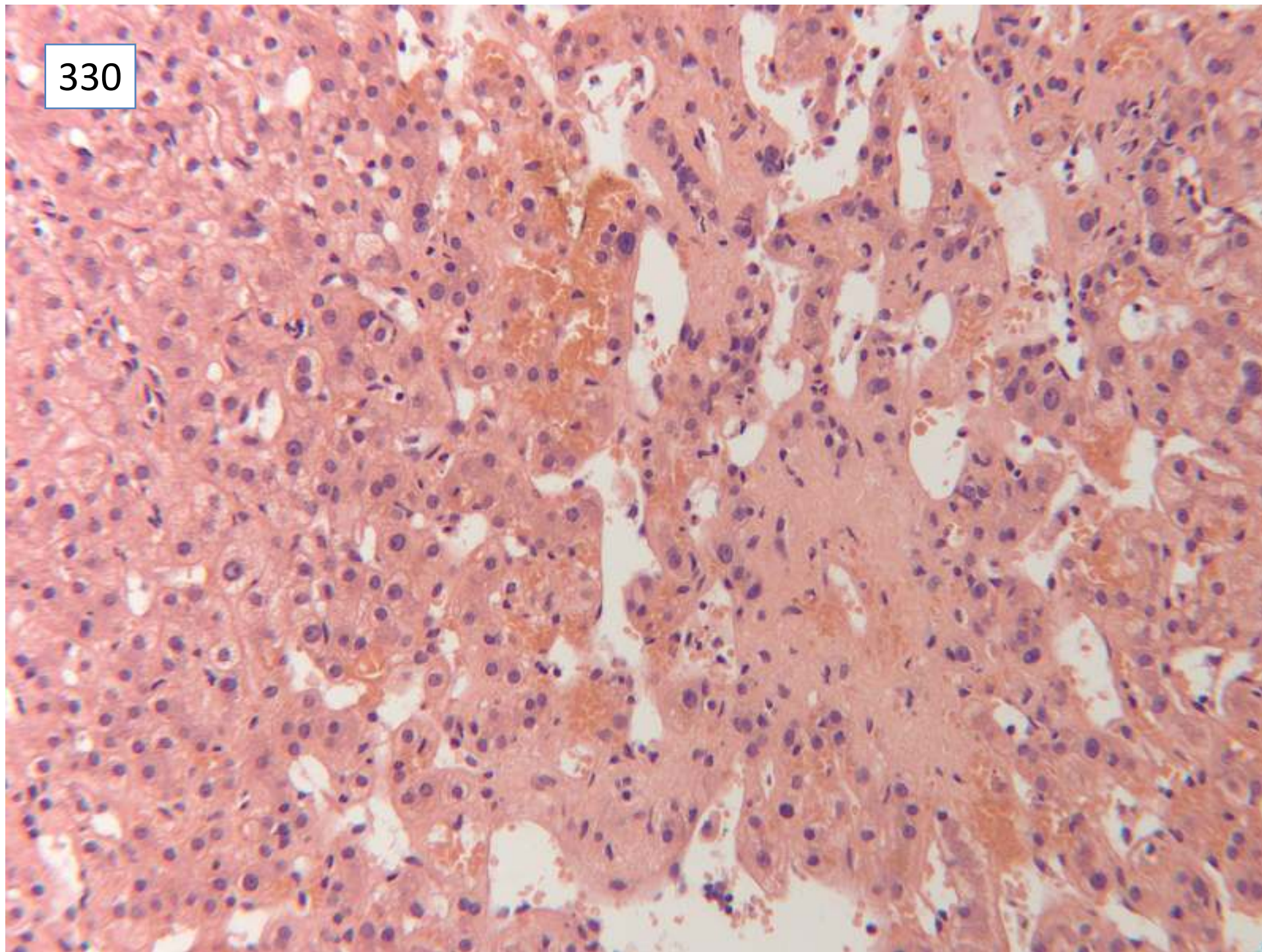
330



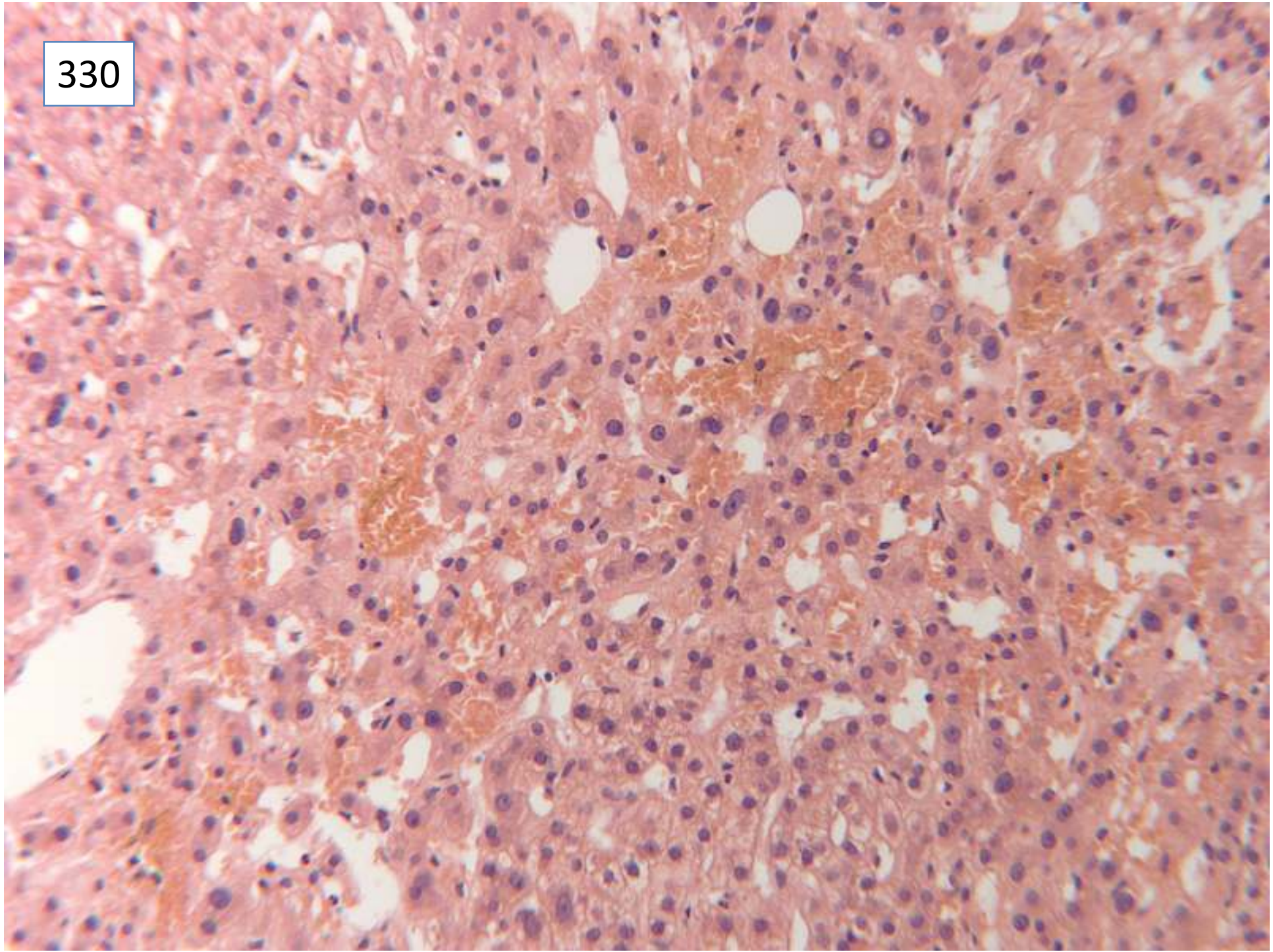
330



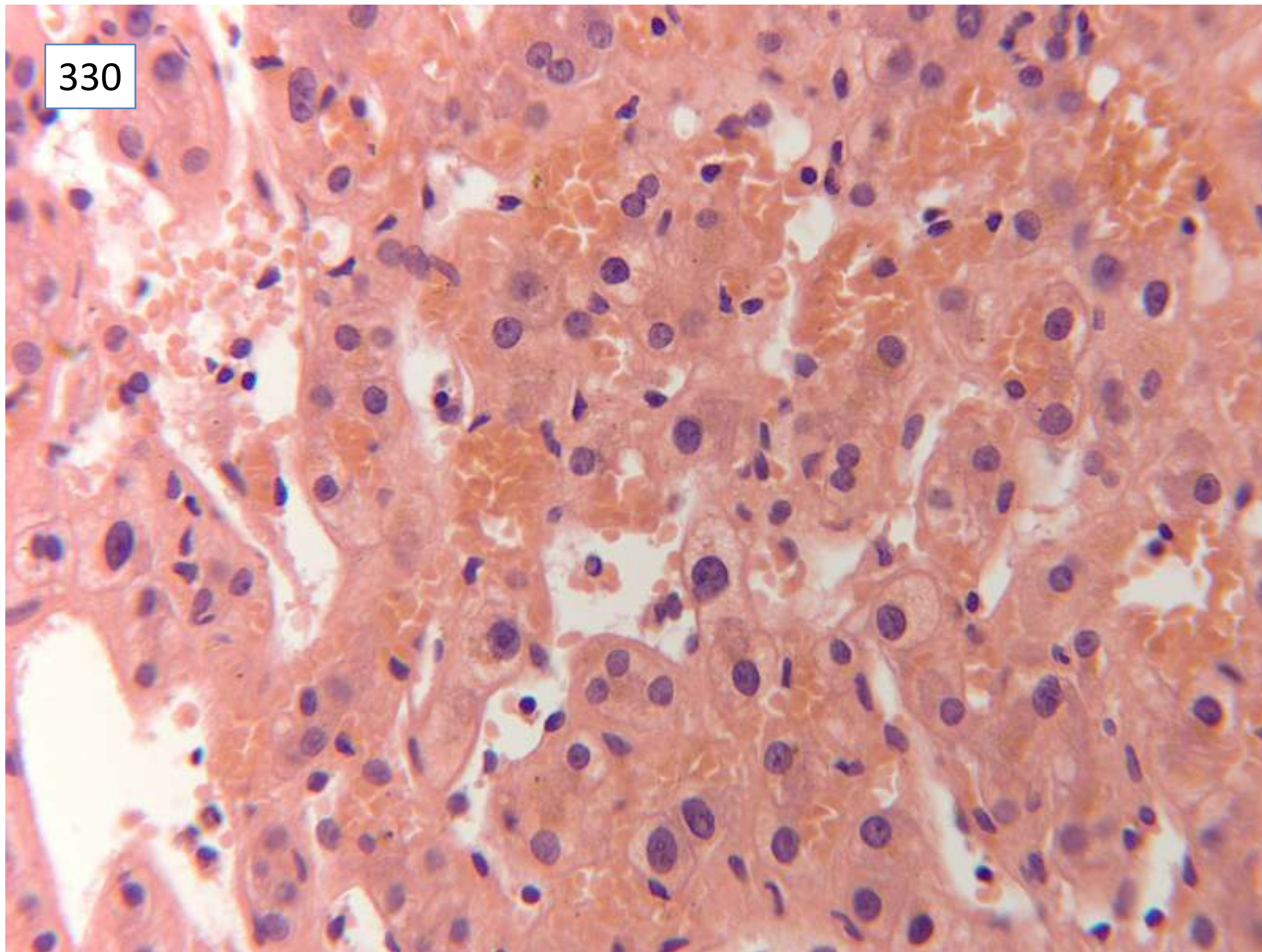
330



330



330



Responses

34 venous outflow obstruction/Budd Chiari syndrome

1 veno-occlusive disease as only diagnosis

1 sinusoidal obstruction syndrome

1 obstructive portal venopathy

1 peliosis

1 portal vein thrombosis

2 nodular regenerative hyperplasia

1 sinusoidal obstruction suggestive of portal vein thrombosis

12 no mention of vascular abnormality

Of which: 9 PSC definite, or consistent with, as only diagnosis

1 ductopaenia, ?sclerosing cholangitis

1 minimal chronic hepatitis, PSC not excluded

1 description, no diagnosis,

1 PSC main diagnosis, ? recent viral hepatitis

2 PSC as secondary diagnosis

1 ? early PBC check autoantibodies

8 PSC possible, not excluded

18 specifically commented on absence of features of PSC

12 no mention of PSC

Case not scored

Scoring and discussion

Case not suitable for scoring – too complicated.

This is a good example of the clinically important features of venous outflow obstruction. The zone 3 hepatocyte loss and red cell extravasation characteristic of Budd Chiari syndrome are well seen.

This led to imaging and pressure studies which confirmed the diagnosis of Budd Chiari syndrome. The hepatic vein was stented and the patient is on warfarin and remains well. ? evidence for PSC as well??

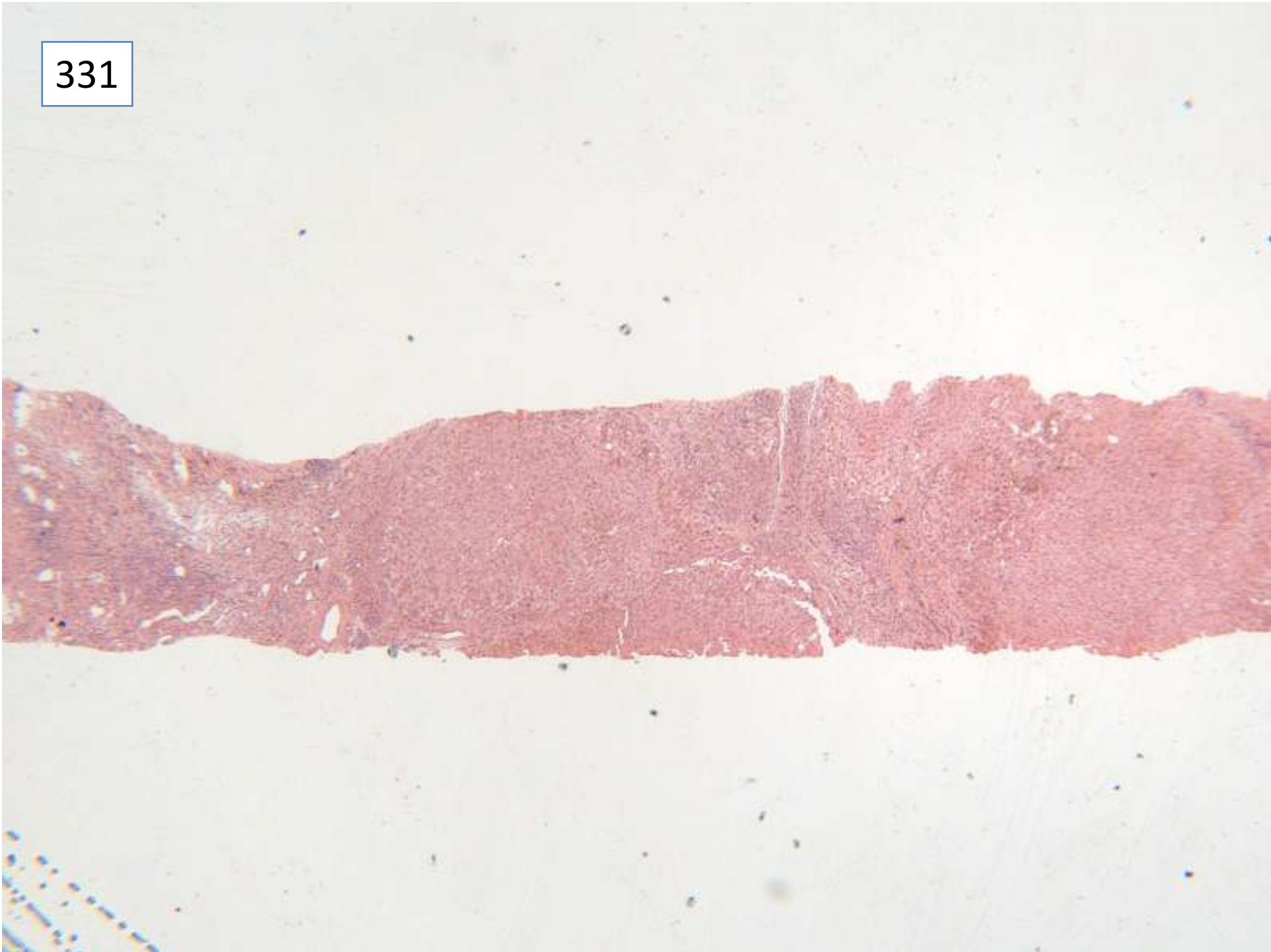Submitting pathologist's diagnosis: Budd Chiari syndrome

Case 331

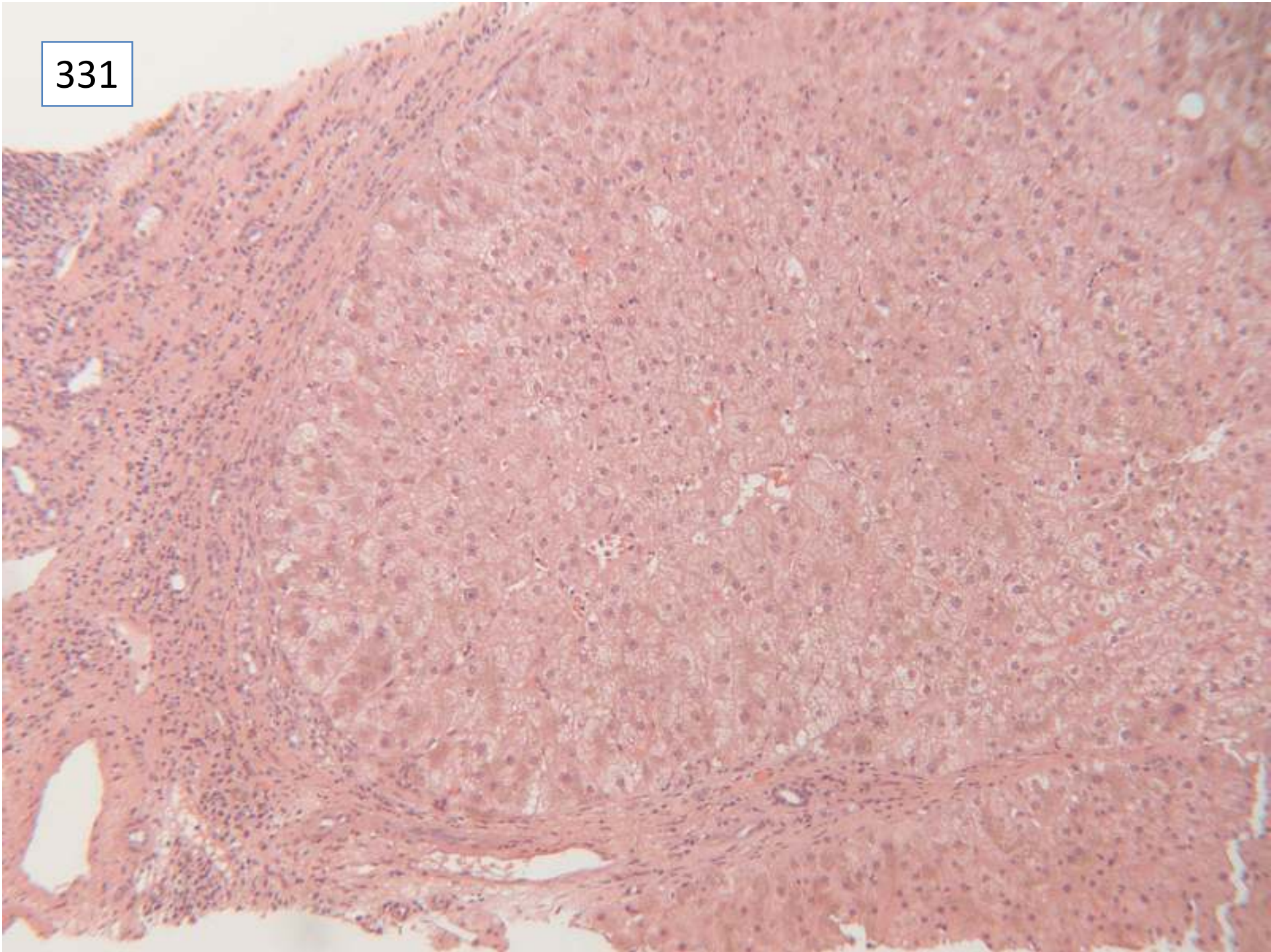
Female 64 years

*Haemochromatosis, 3 litres drained from
ascites*

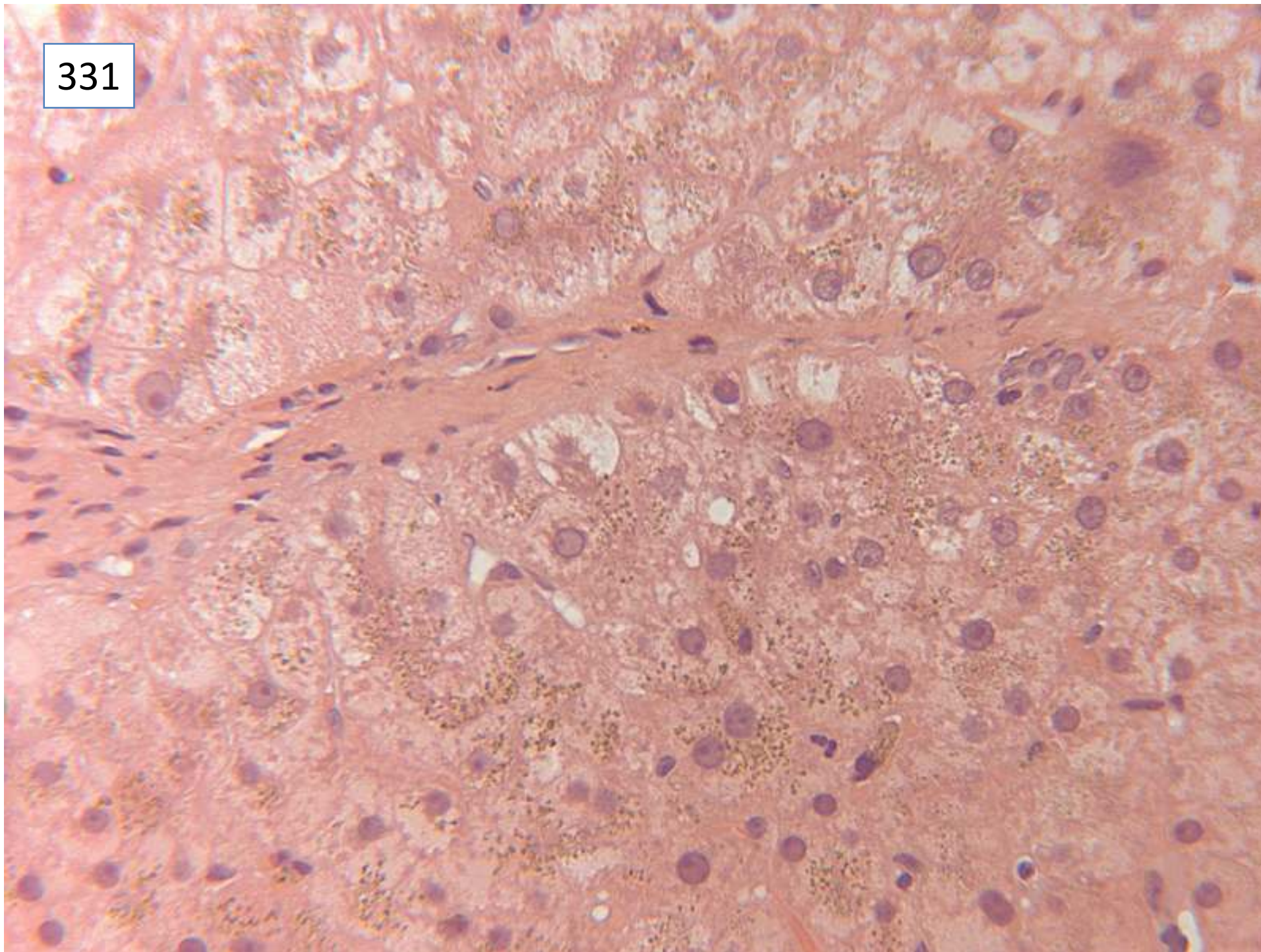
331



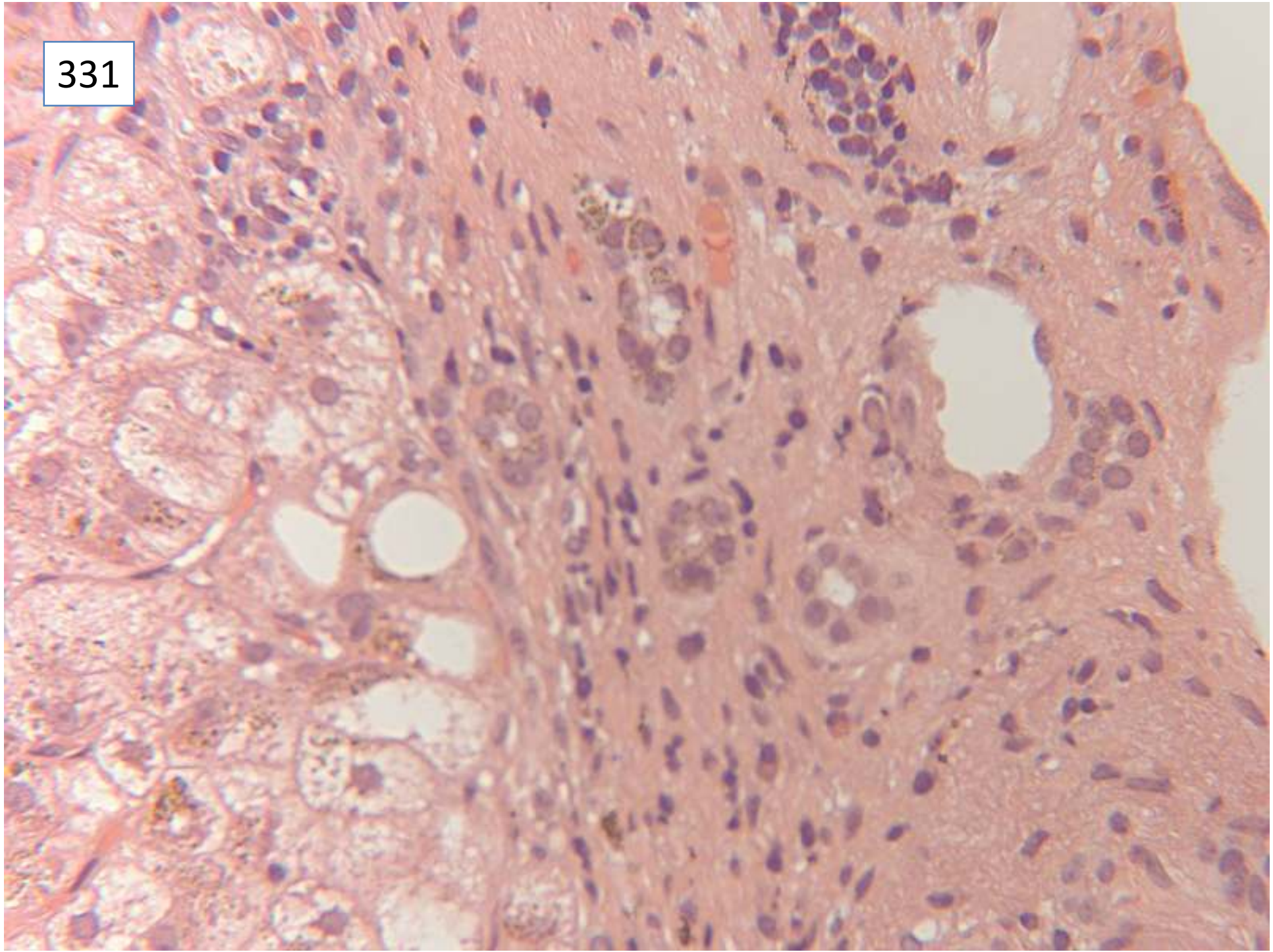
331



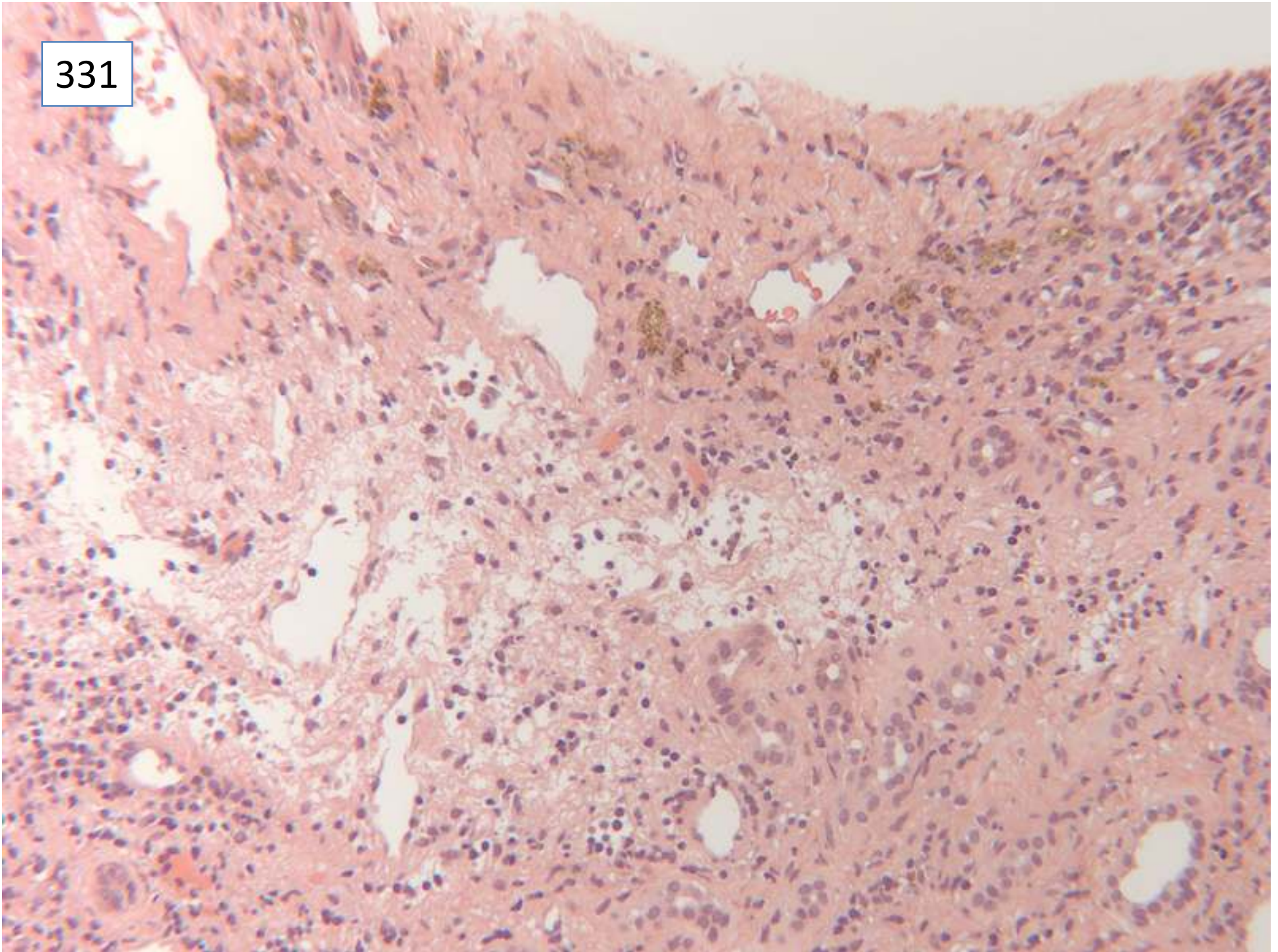
331



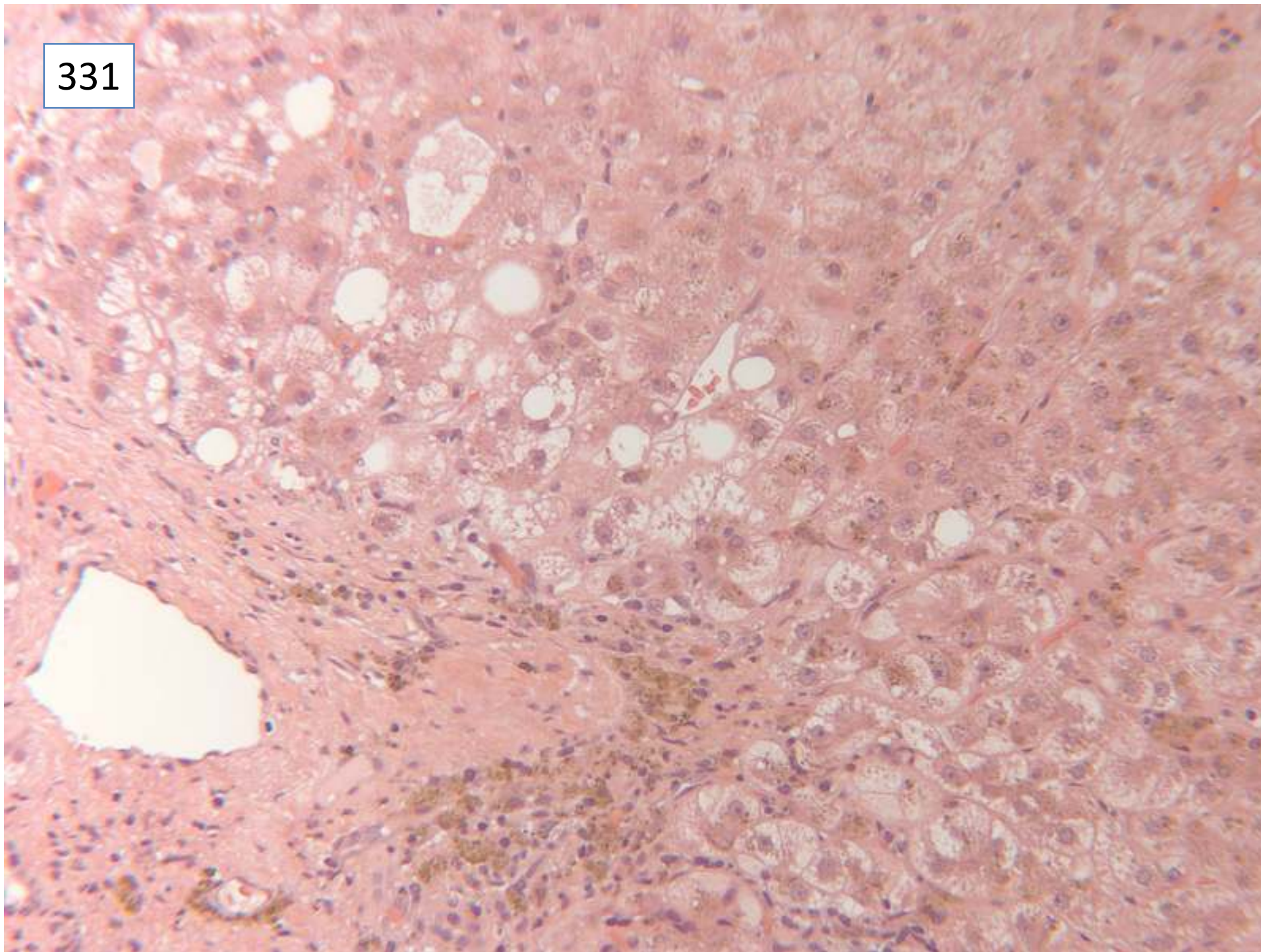
331



331



331



Responses

54 cirrhosis

1 cirrhosis not mentioned

54 haemochromatosis

1 siderosis (not further qualified)

9 specifically commented on absence of
dysplasia/malignancy

7 also ? fatty liver disease

1 large cell dysplasia

331

Scoring and discussion

Both cirrhosis and haemochromatosis needed to be included for full marks.

Submitting pathologist's diagnosis: cirrhosis, haemochromatosis

Case 332

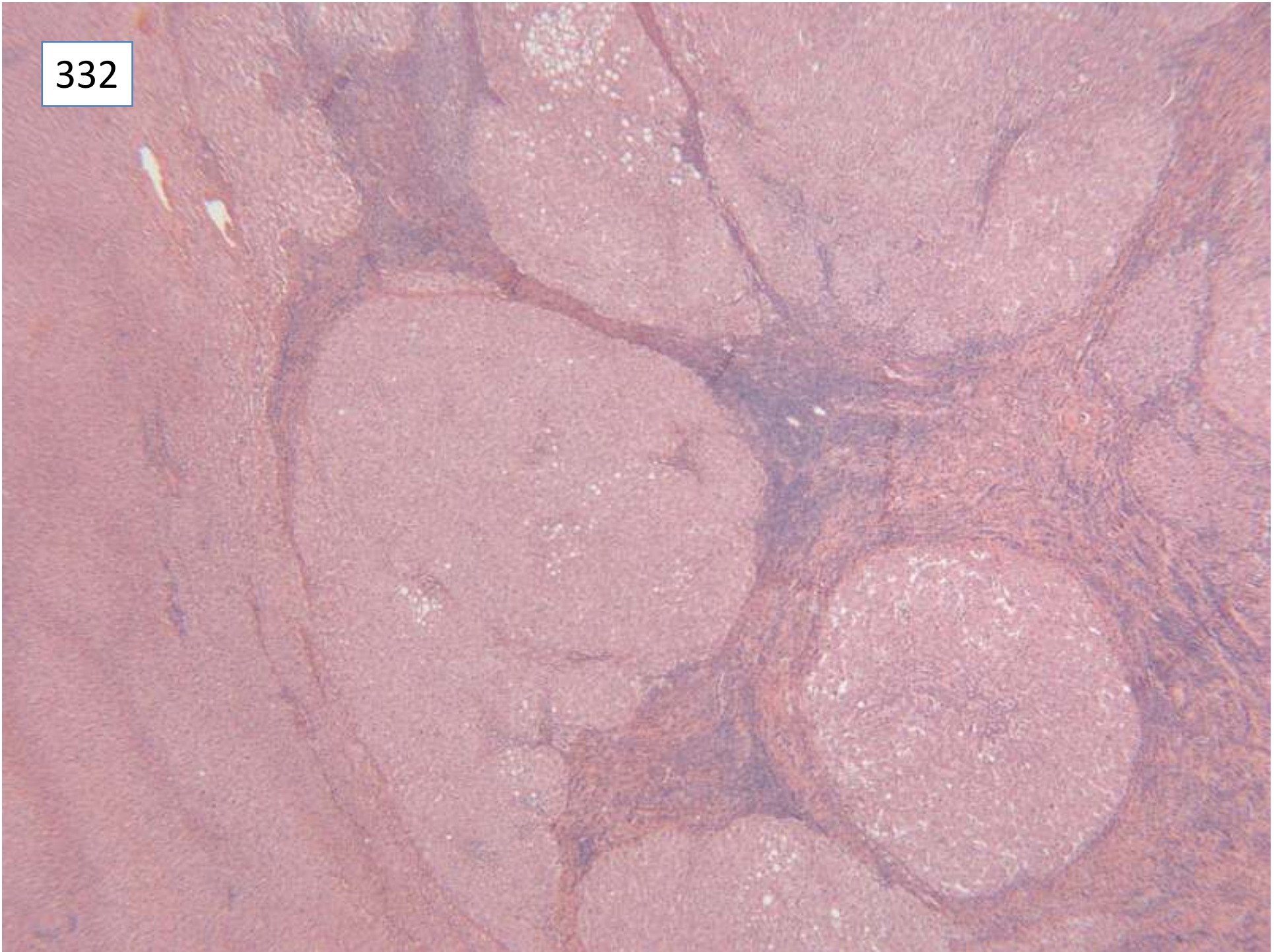
Female 55 years

Liver resection for adenoma

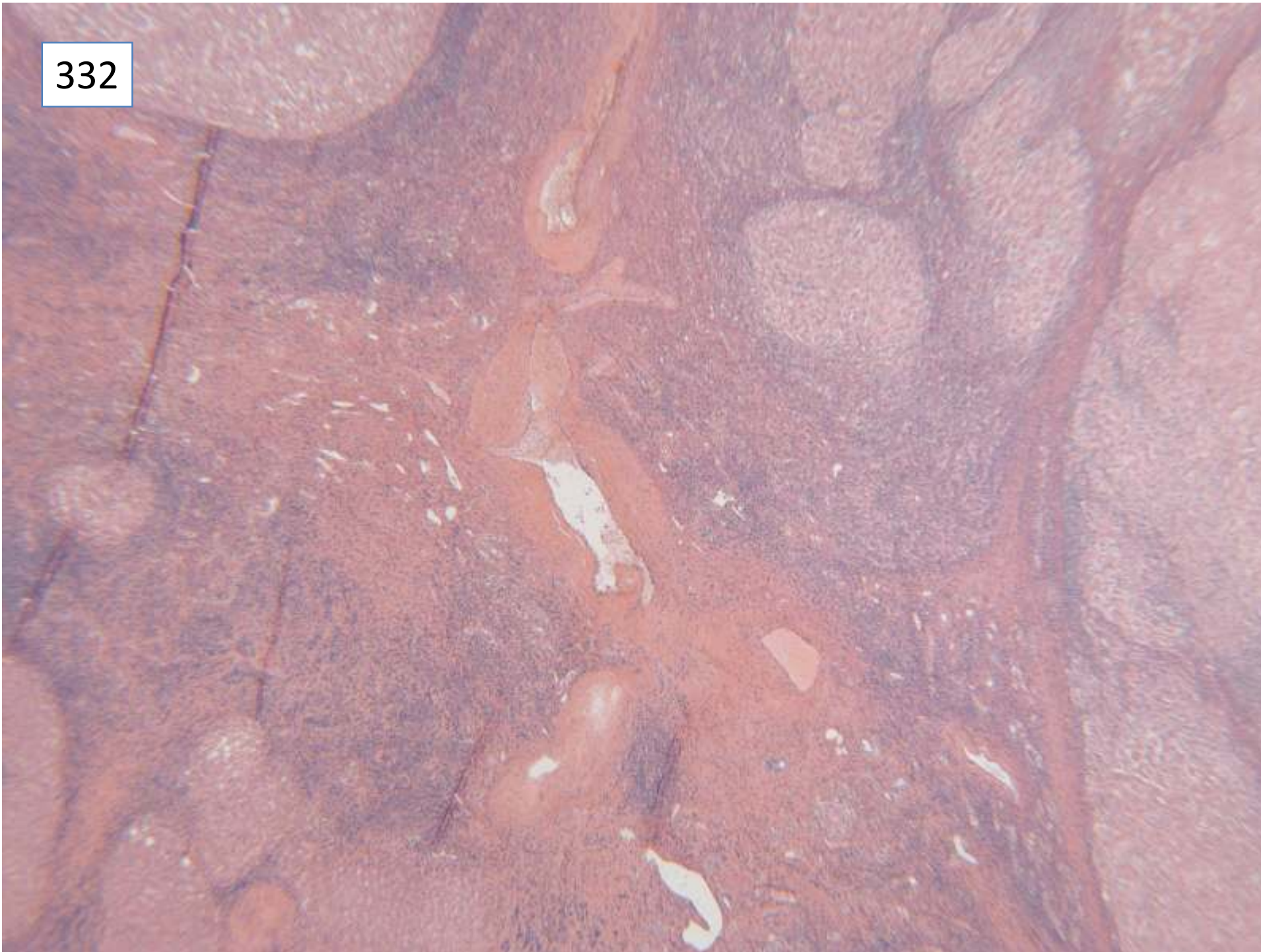
Specimen: Liver resection

Macroscopic description: Nodular segment of liver measuring 3.8x2x1.8cm. on section there was a multinodular lesion 2.2x2x.1.4cm

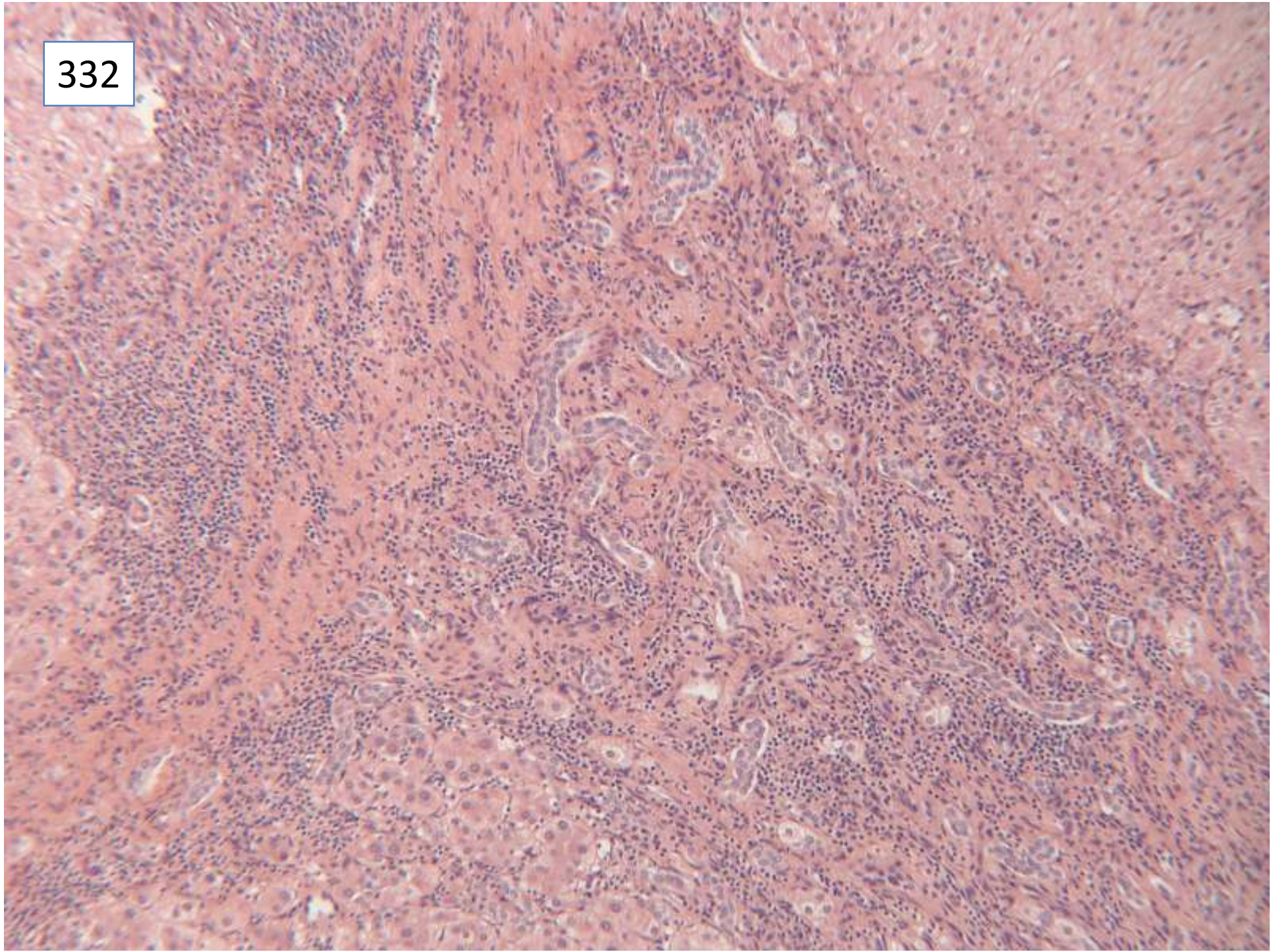
332



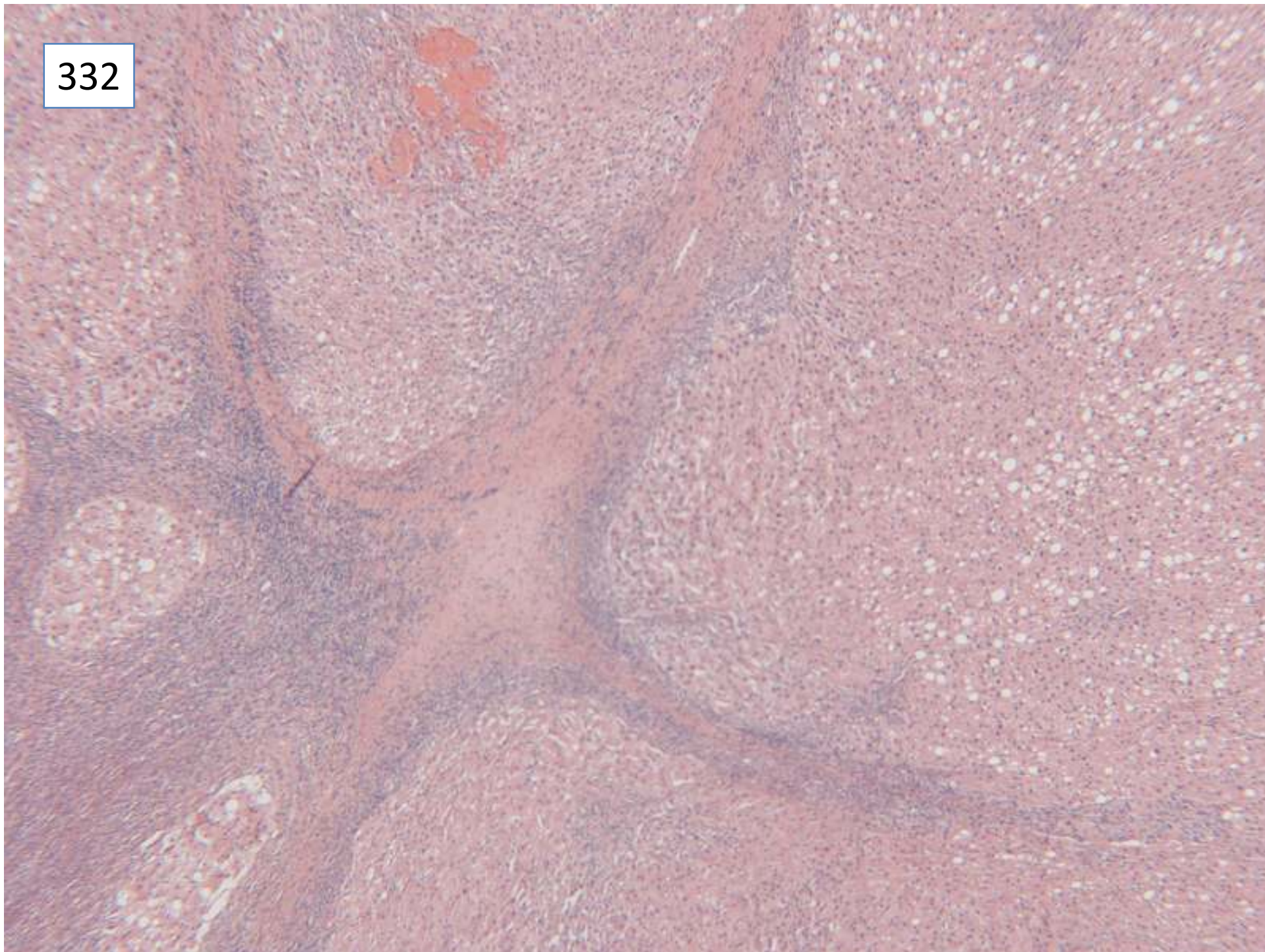
332



332



332



Responses

52 focal nodular hyperplasia

1 FNH or FNH-like adenoma

1 benign liver adenoma

1 follicular nodular hyperplasia

Scoring and discussion

This case showed unequivocal characteristic features of a focal nodular hyperplasia, including stellate fibrosis with thick walled artery, ductular reaction and chronic inflammation.

Score 0 for adenoma or 'FNH or FNH-like adenoma' – this case did not have the features of a telangiectatic FNH, the type of FNH which is now re-classified as an adenoma. Score 5 marks for 'follicular nodular hyperplasia' – presumed a typographical error.

Submitting pathologist's diagnosis:

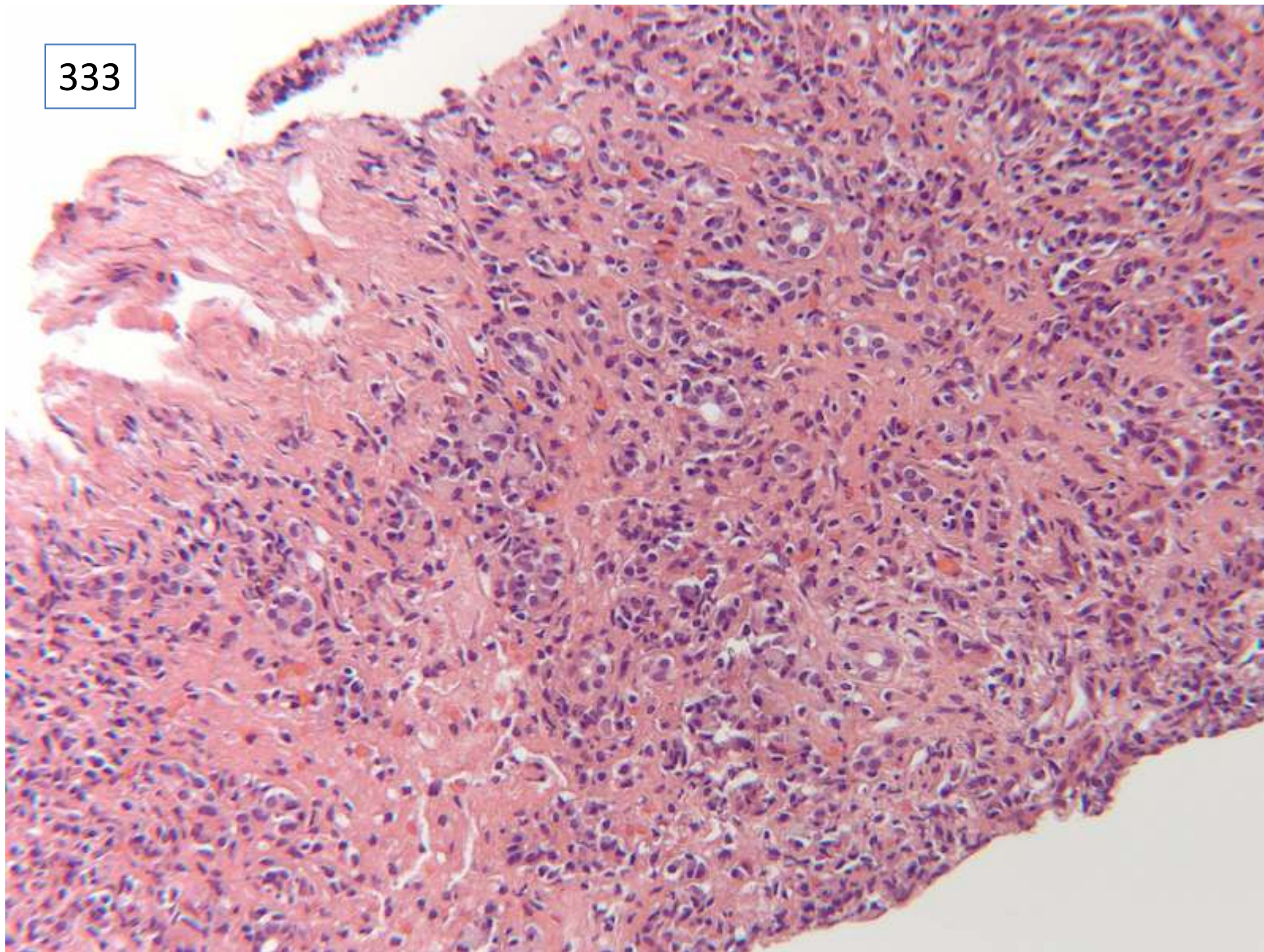
Focal nodular hyperplasia

Case 333

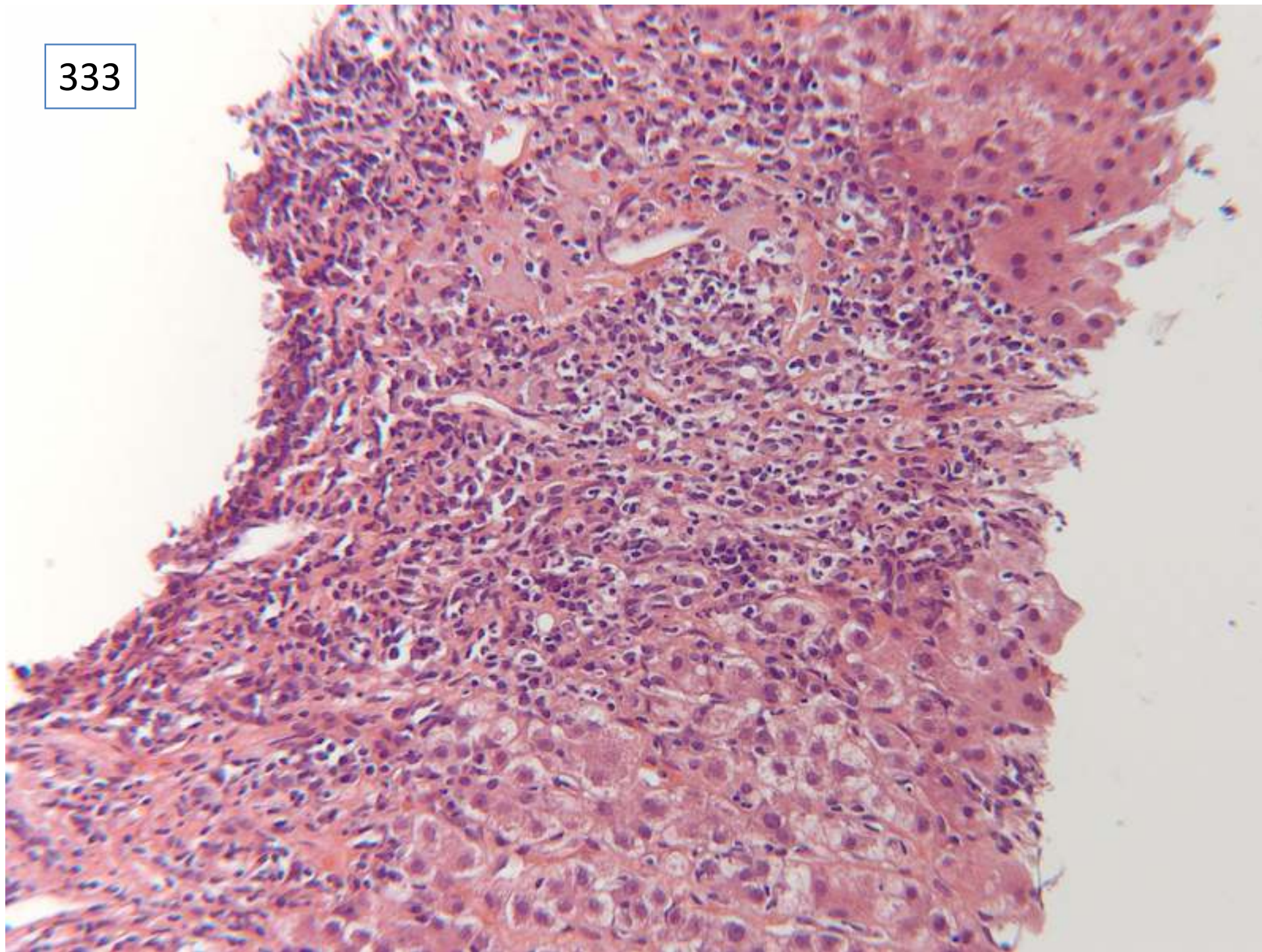
Female 34 years

Acute abnormal LFT's. Increased IgG (40). Positive ANA and SMA. Negative other serology. Likely autoimmune hepatitis

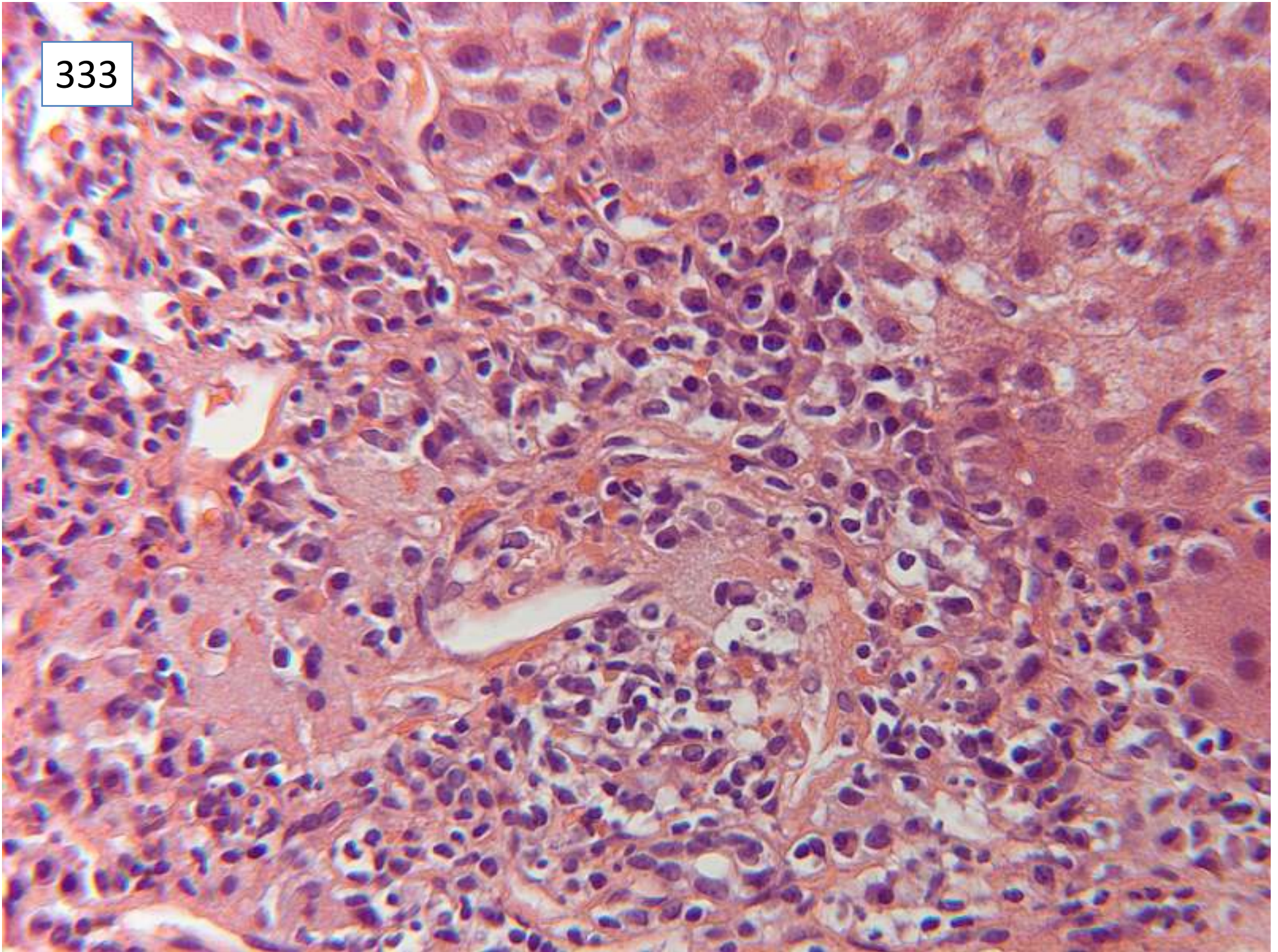
333



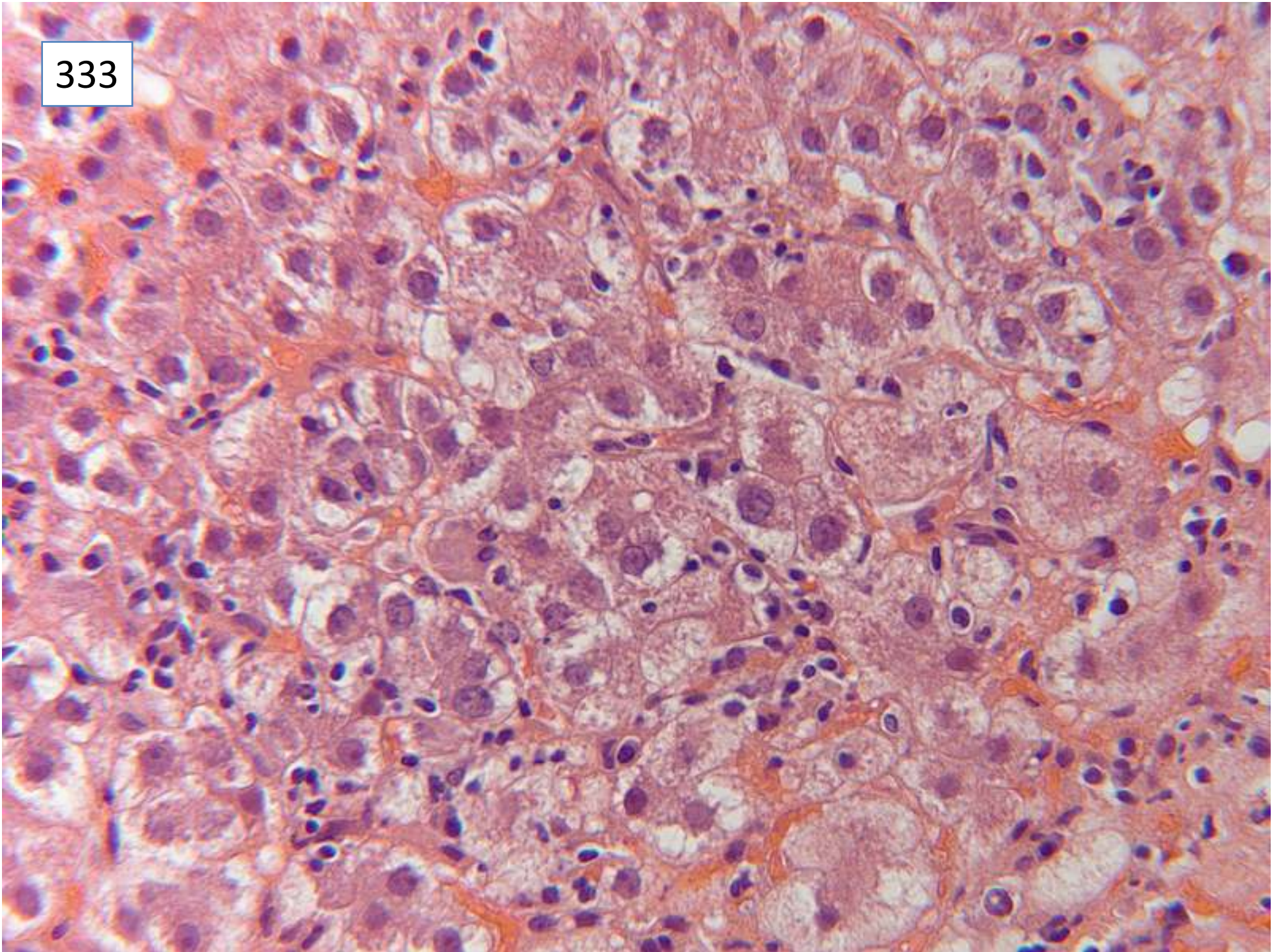
333



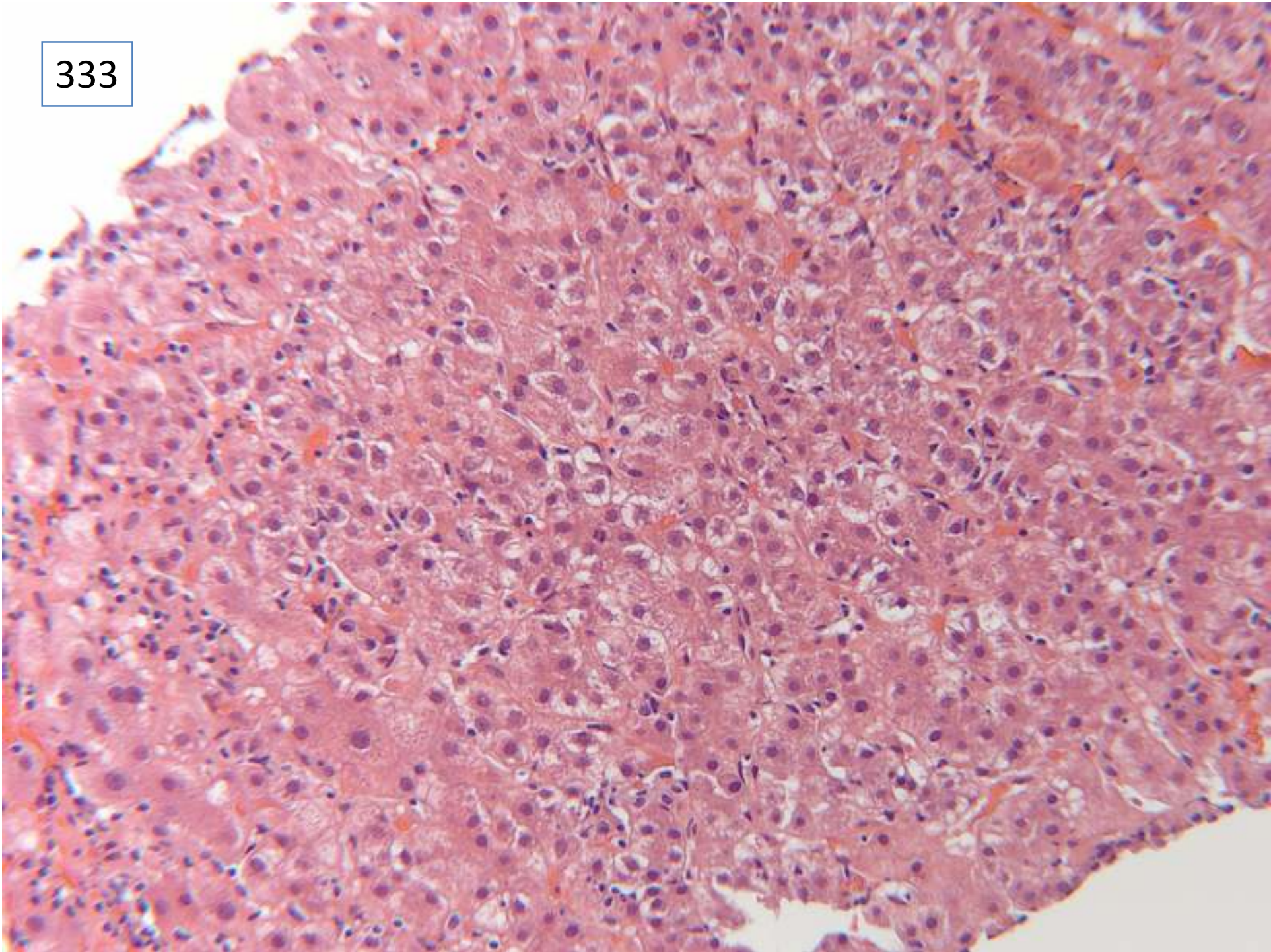
333



333



333



ResponsesMorphology:

6 acute hepatitis

17 acute hepatitis with bridging/confluent necrosis

12 hepatitis,

4 acute on chronic hepatitis

10 chronic active hepatitis

4 *chronic hepatitis*

1 *autoimmune hepatitis and cirrhosis*

1 *lupoid hepatitis*

37 specifically commented on prominence of plasma cells

Aetiology:

40 Autoimmune hepatitis as only diagnosis

9 autoimmune hepatitis as main diagnosis, with differential

1 *lupoid hepatitis*

4 *autoimmune hepatitis/primary biliary cirrhosis overlap*

Scoring and discussion

For full marks, needed mention of activity of hepatitis, and of autoimmune aetiology. Responses with chronic hepatitis or cirrhosis without a comment on activity of disease were deducted 5 marks. Lupoid hepatitis is obsolete terminology, replaced by autoimmune hepatitis. There were neither histological or clinical features to suggest an additional component of an overlap syndrome with PBC.

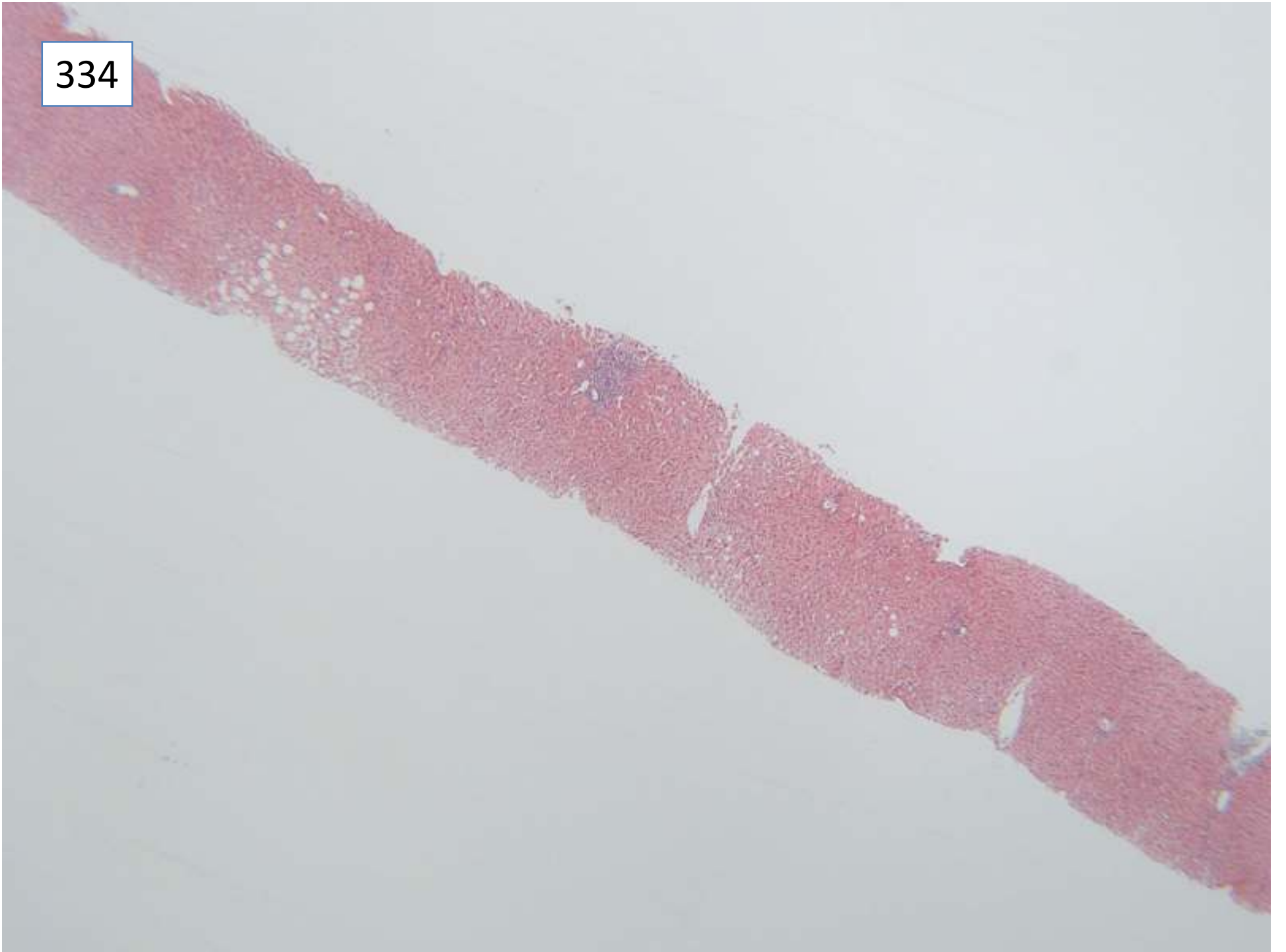Submitting pathologist's diagnosis: florid autoimmune hepatitis with prominent confluent /submassive necrosis

Case 334

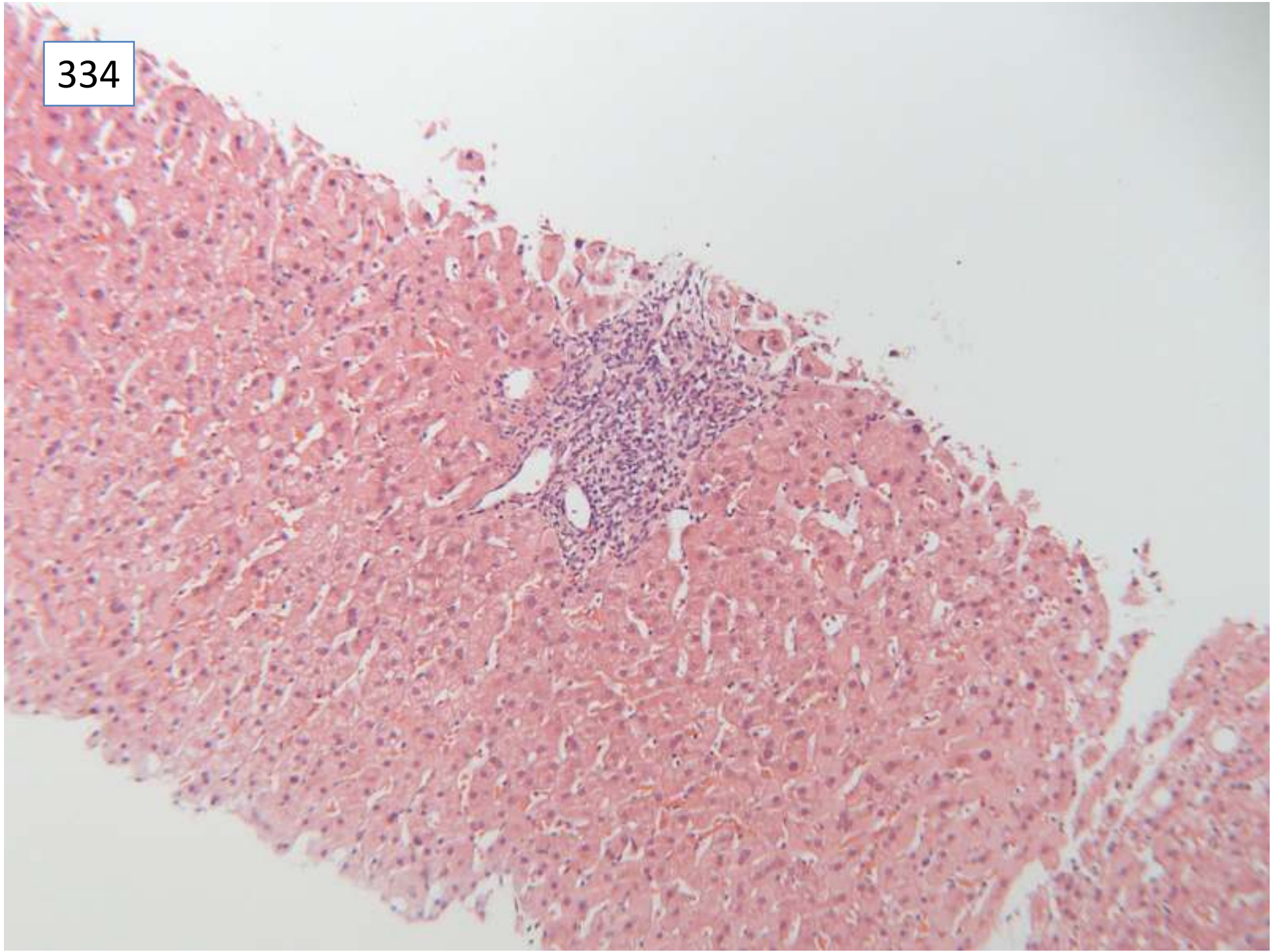
Male 34 years

Hepatitis B positive. Fatty liver? Cause.

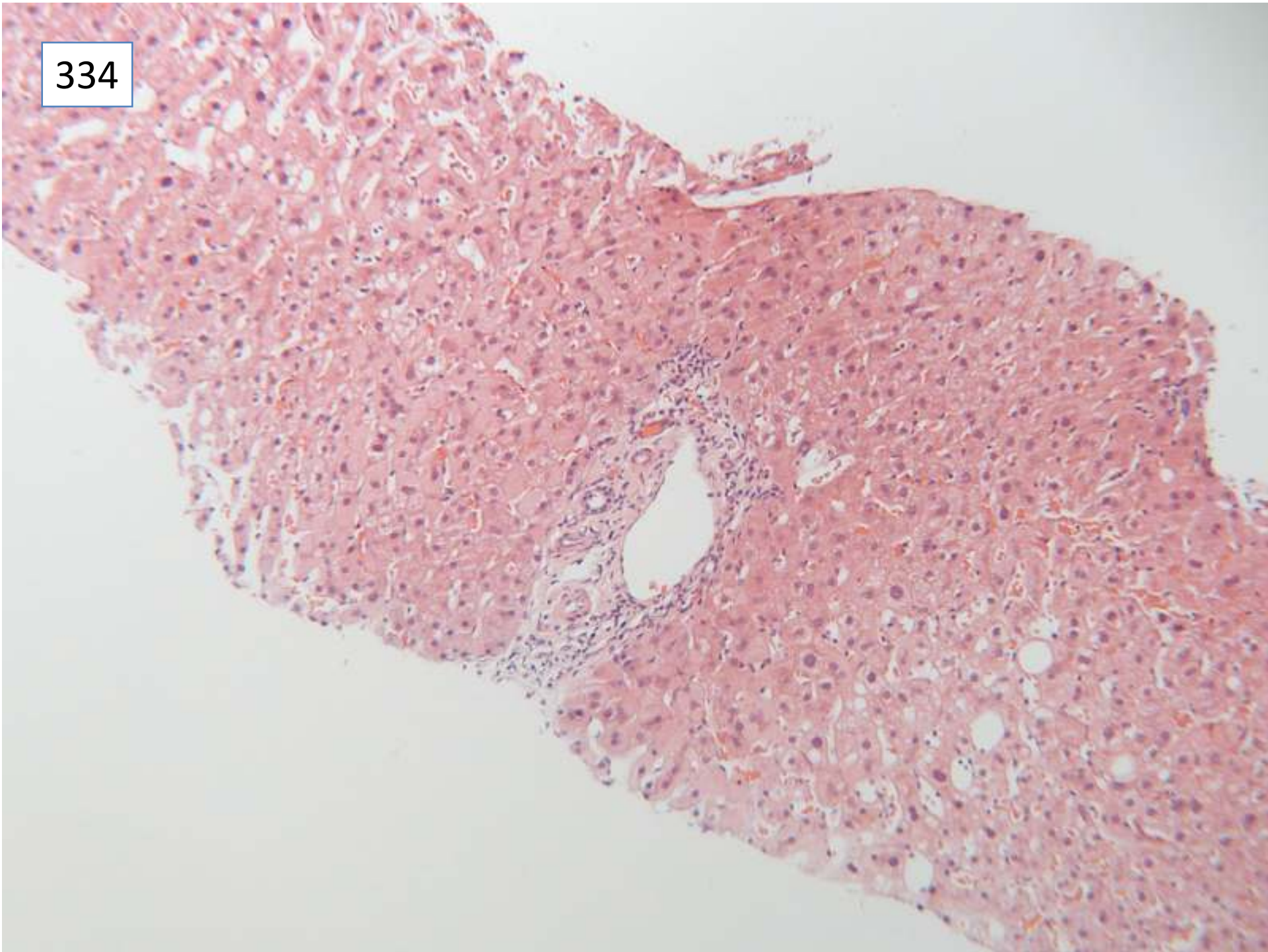
334



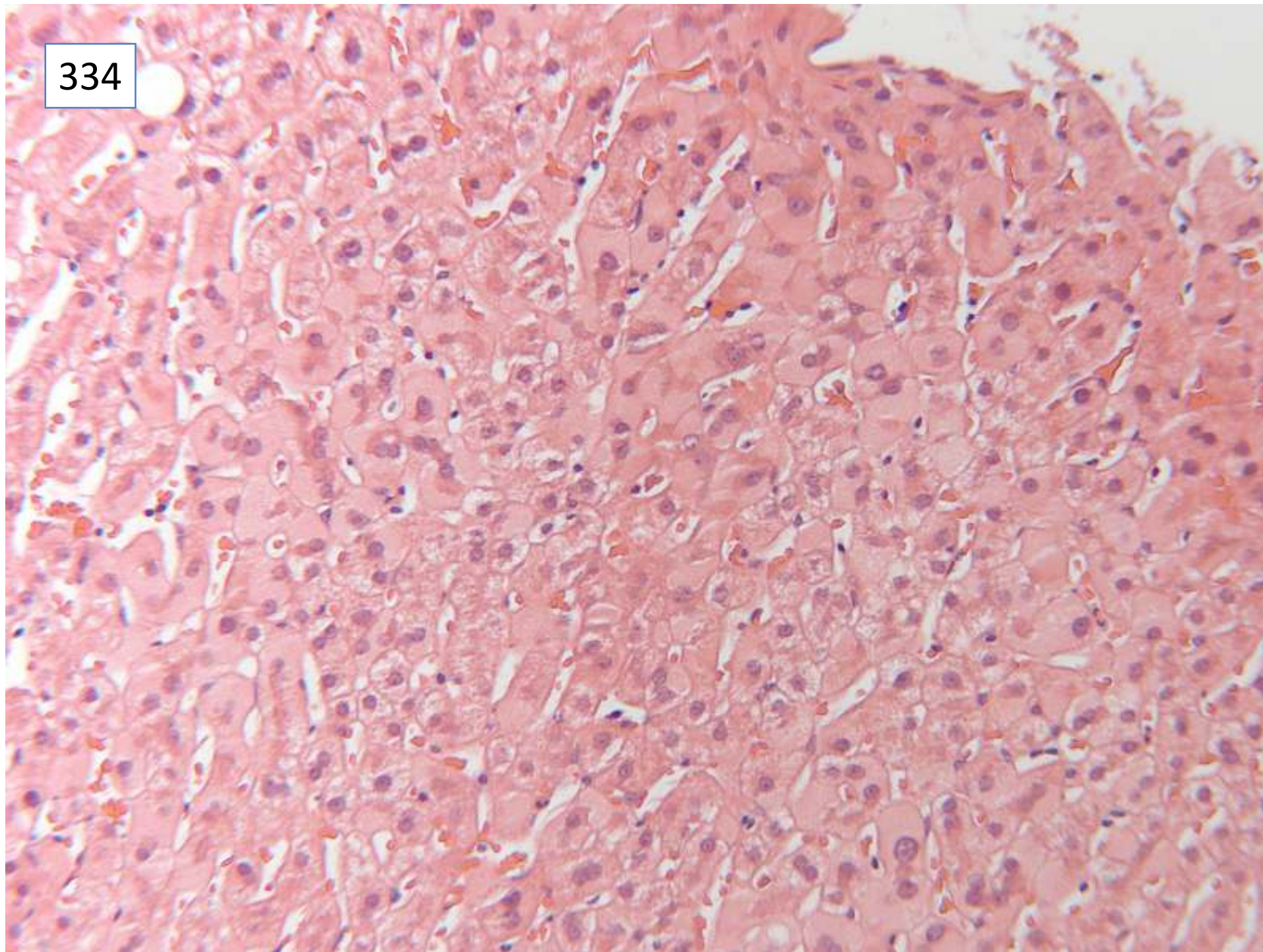
334



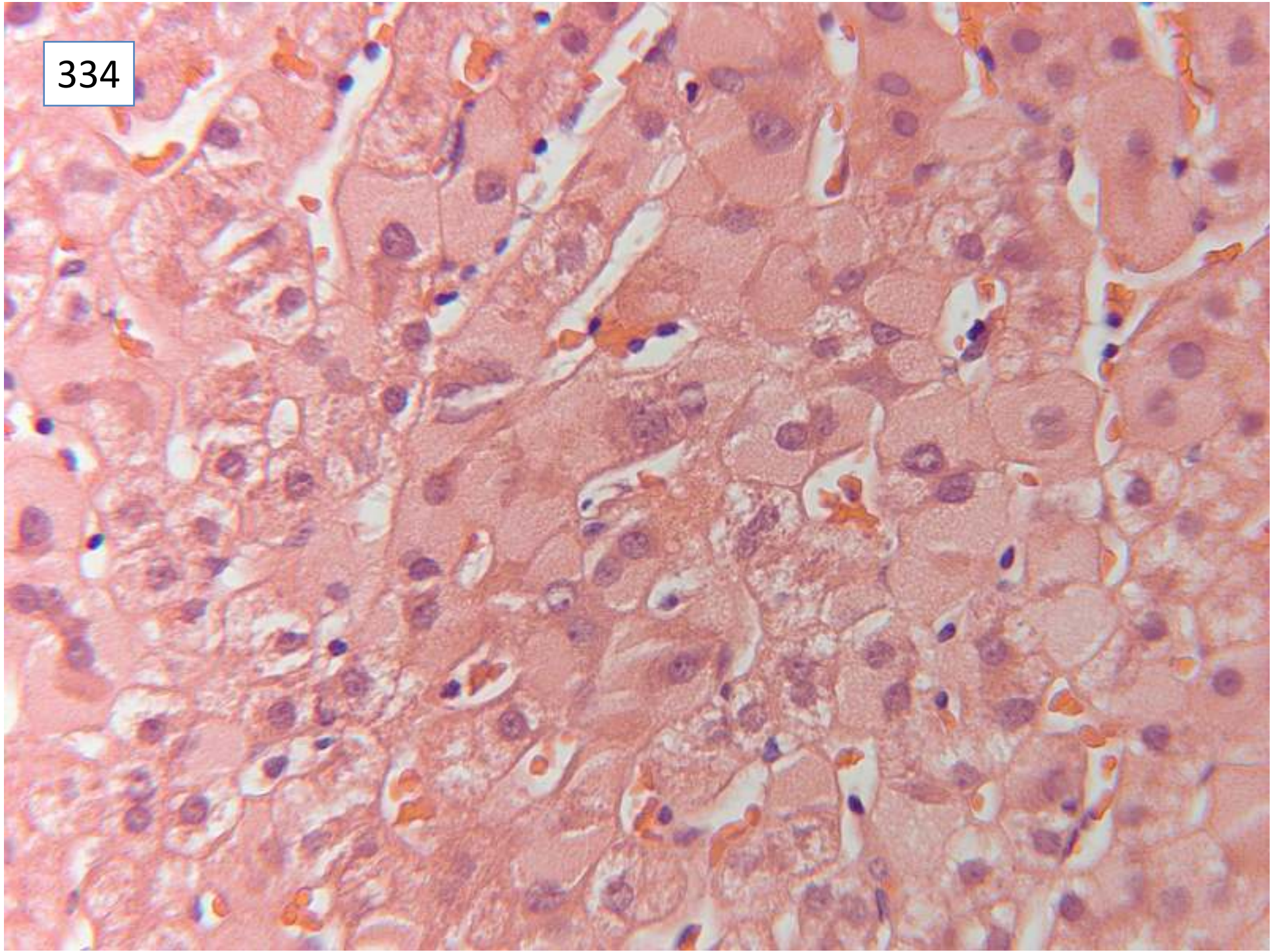
334



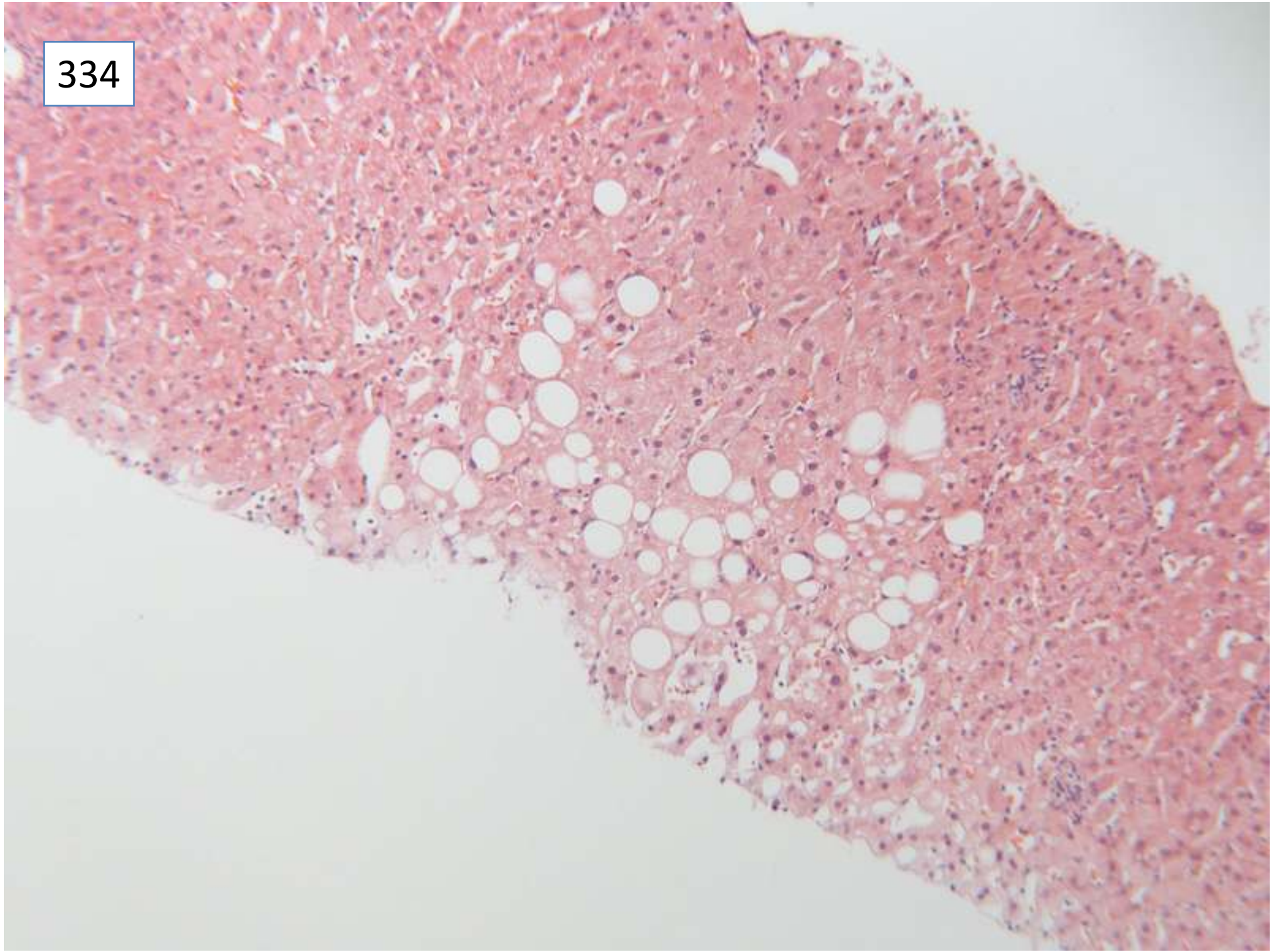
334



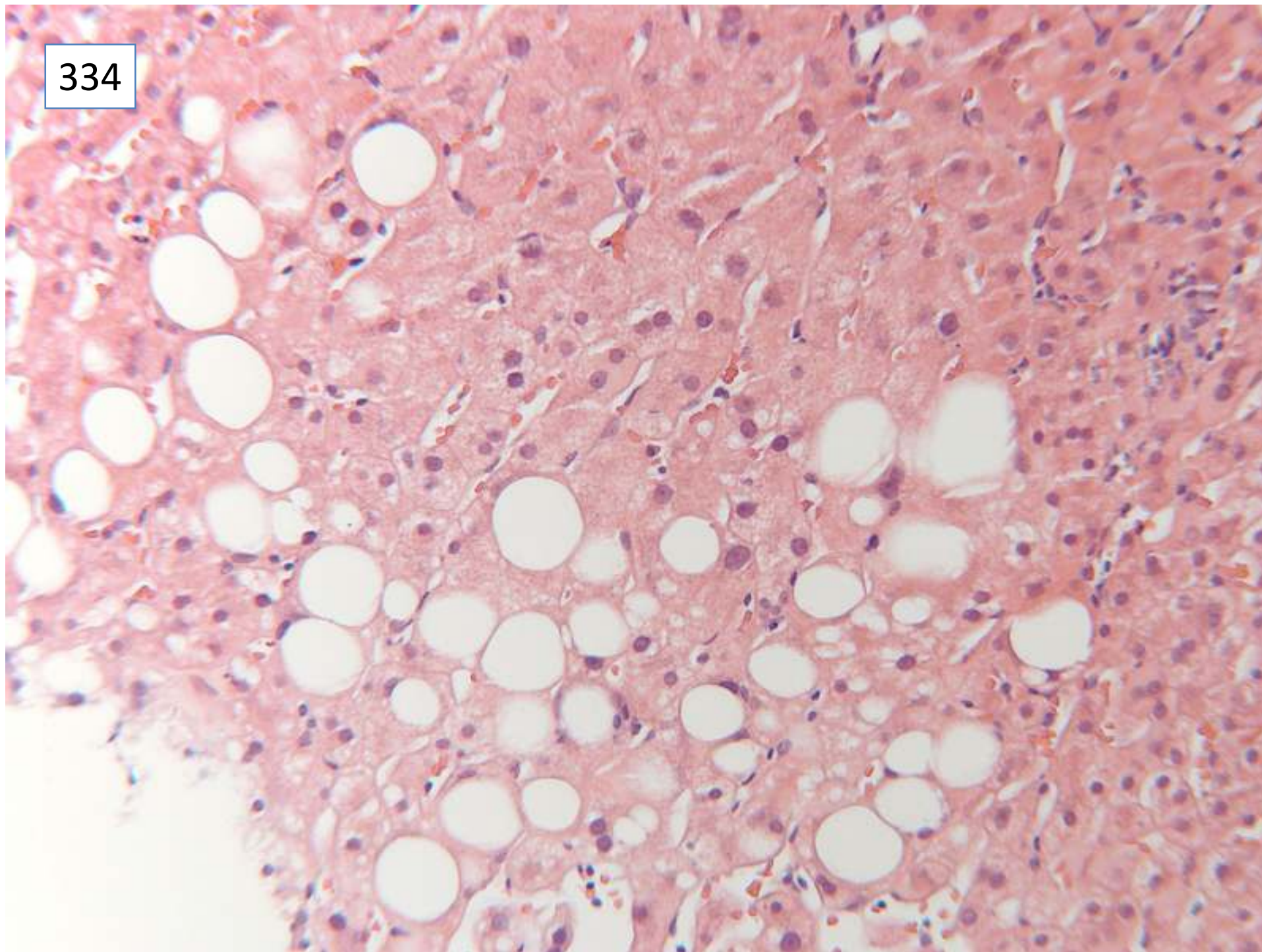
334



334



334



Responses

3 Chronic hepatitis, NOS

18 chronic hepatitis, minimal

28 chronic hepatitis, mild

1 hepatitis B carrier

1 'hepatitis B infection' – no mention of chronic hepatitis histologically

1 no portal or acinar inflammation

1 'no portal or parenchymal inflammation. No evidence of NASH or active hepatitis B hepatitis'

1 'no changes of active viral hepatitis' (ground glass not mentioned)

50 ground glass hepatocytes / hepatitis B mentioned

4 ground glass/hepatitis B not mentioned

45 steatosis, mild

1 steatosis, moderate

3 steatosis, NOS

1 no steatosis

1 steatohepatitis

1 micro and macrovesicular steatosis, ? drug

2 steatosis not mentioned

Scoring and discussion

For full marks, responses needed to include the presence of chronic hepatitis, ground glass hepatocytes, and steatosis.

Although mild there was sufficient portal inflammation in some portal tracts to support a diagnosis of chronic hepatitis. The clinical information queried fatty liver, and a comment on the presence of steatosis was therefore required for full marks. There were no ballooned hepatocytes or other features of steatohepatitis.

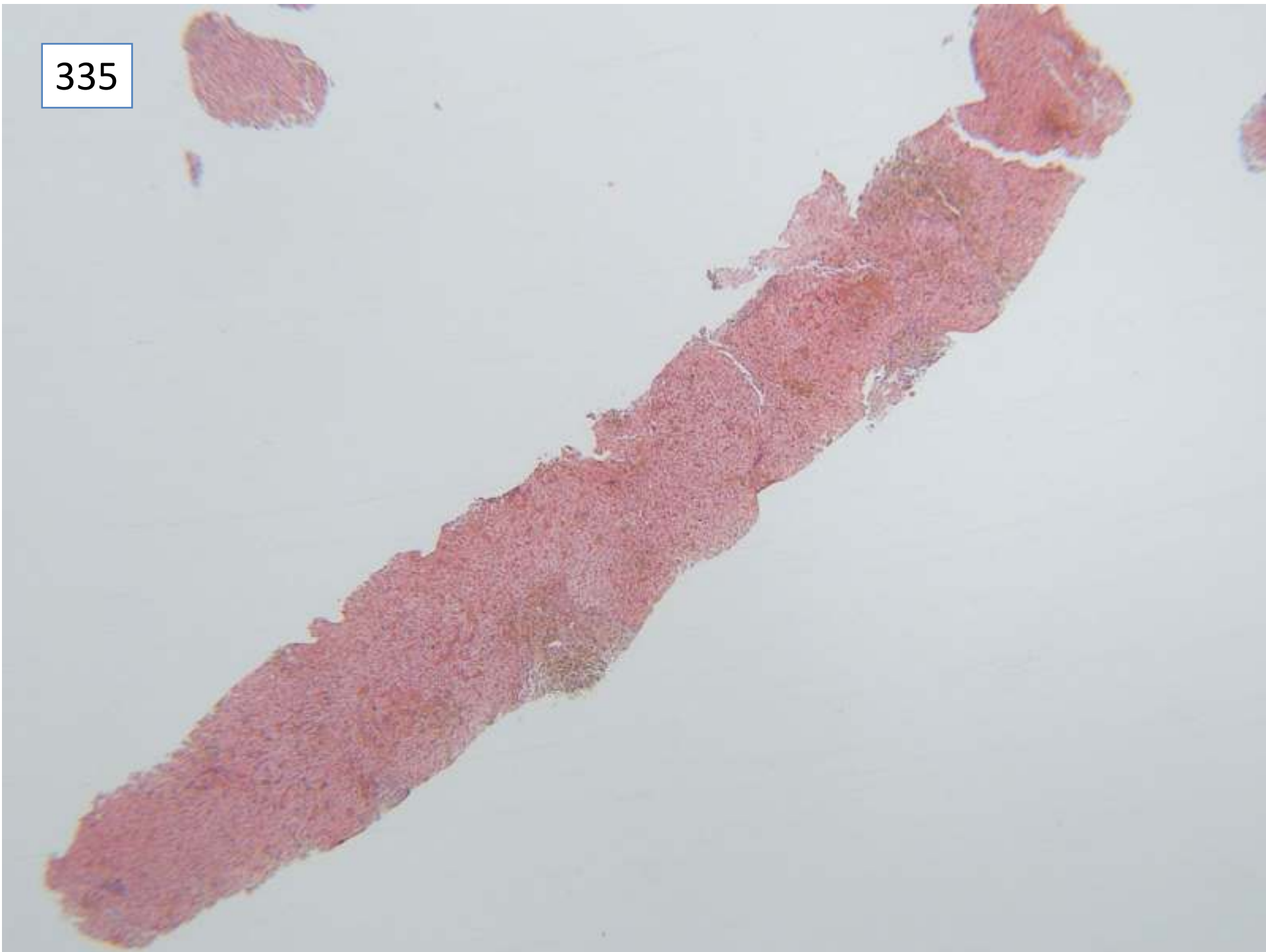
Submitting pathologist's diagnosis: minimal chronic hepatitis B, stage 0, no steatosis

Case 335

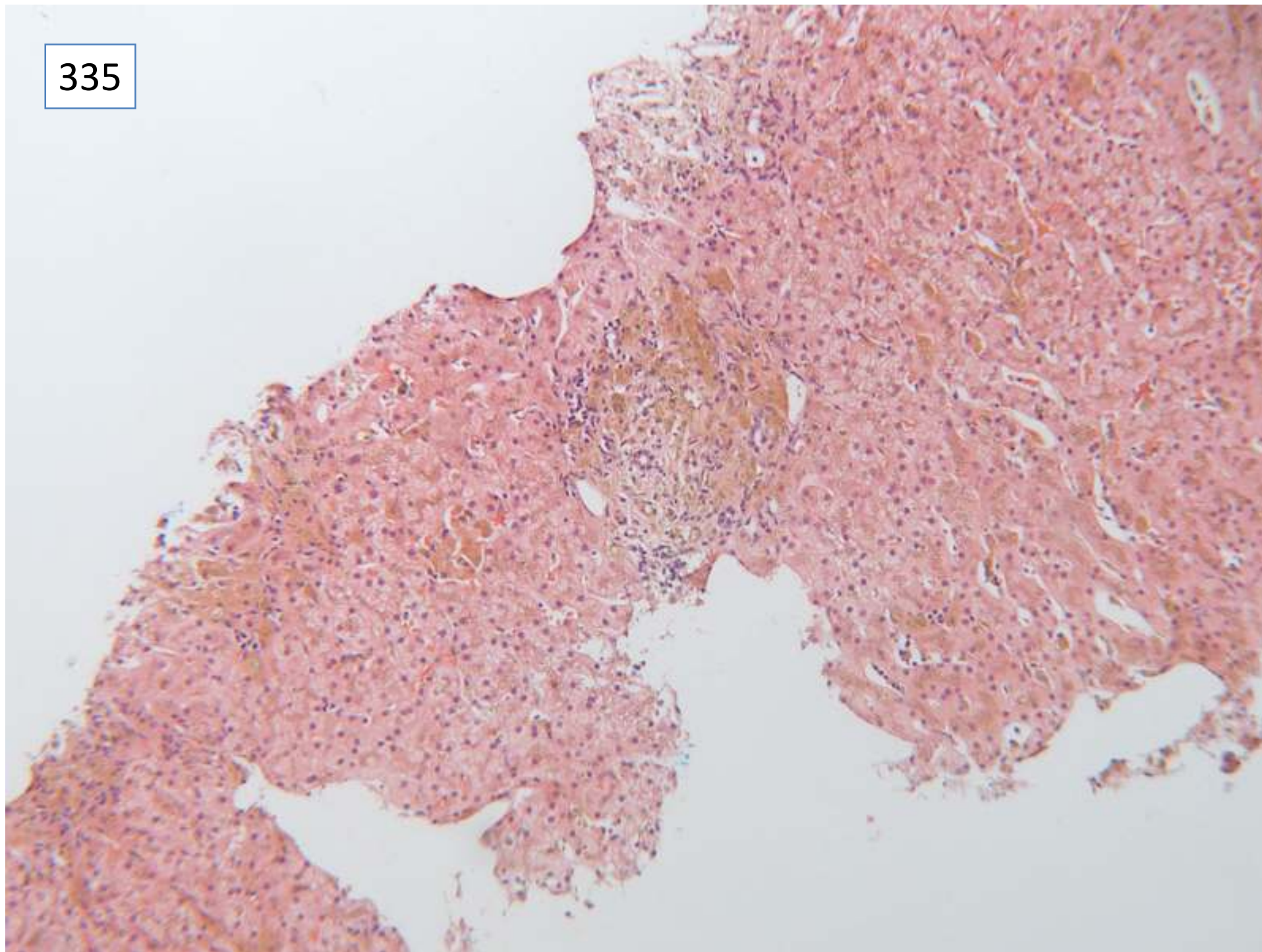
Female 25 years

beta Thalassaemia. Increased ferritin

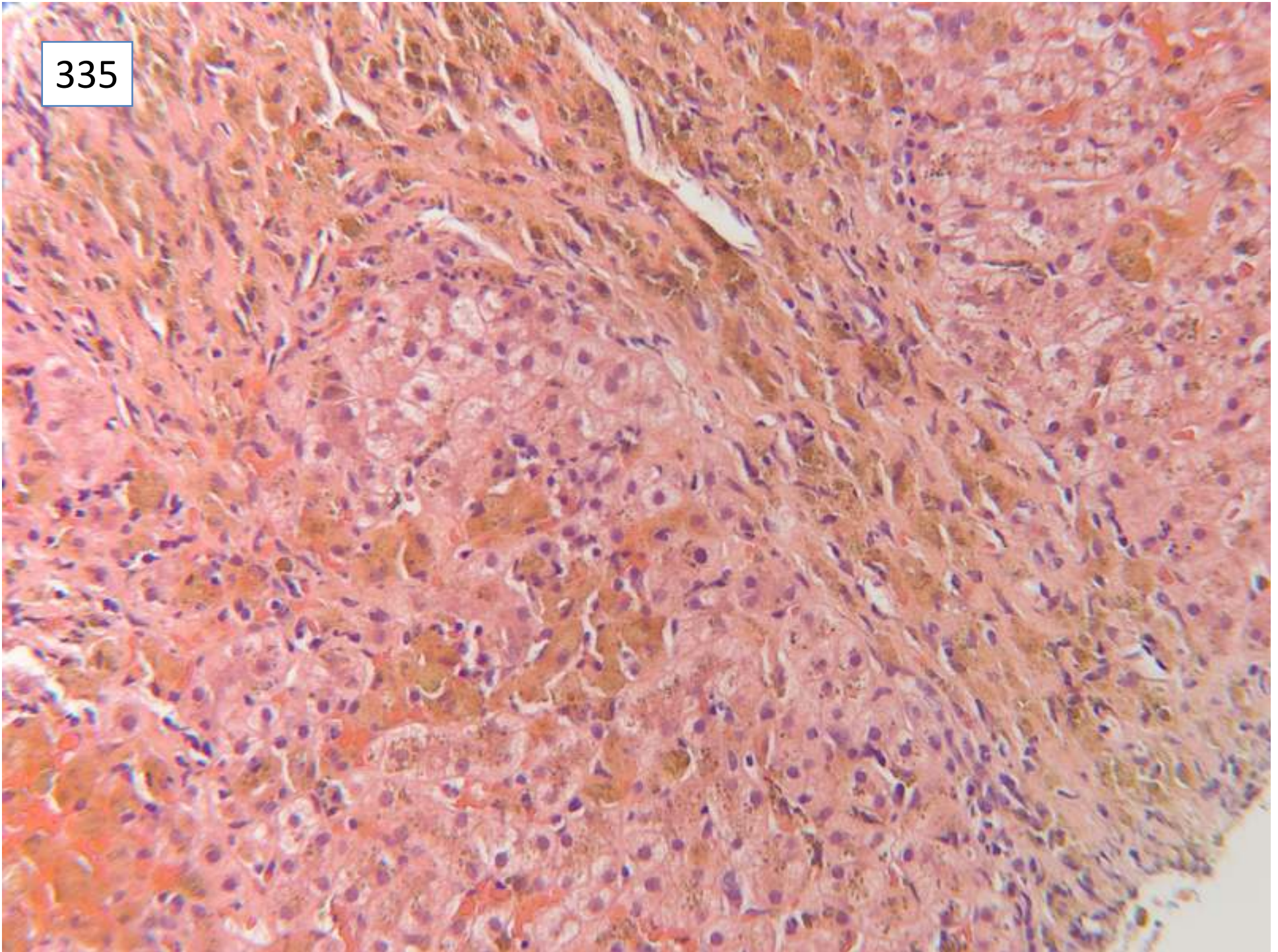
335



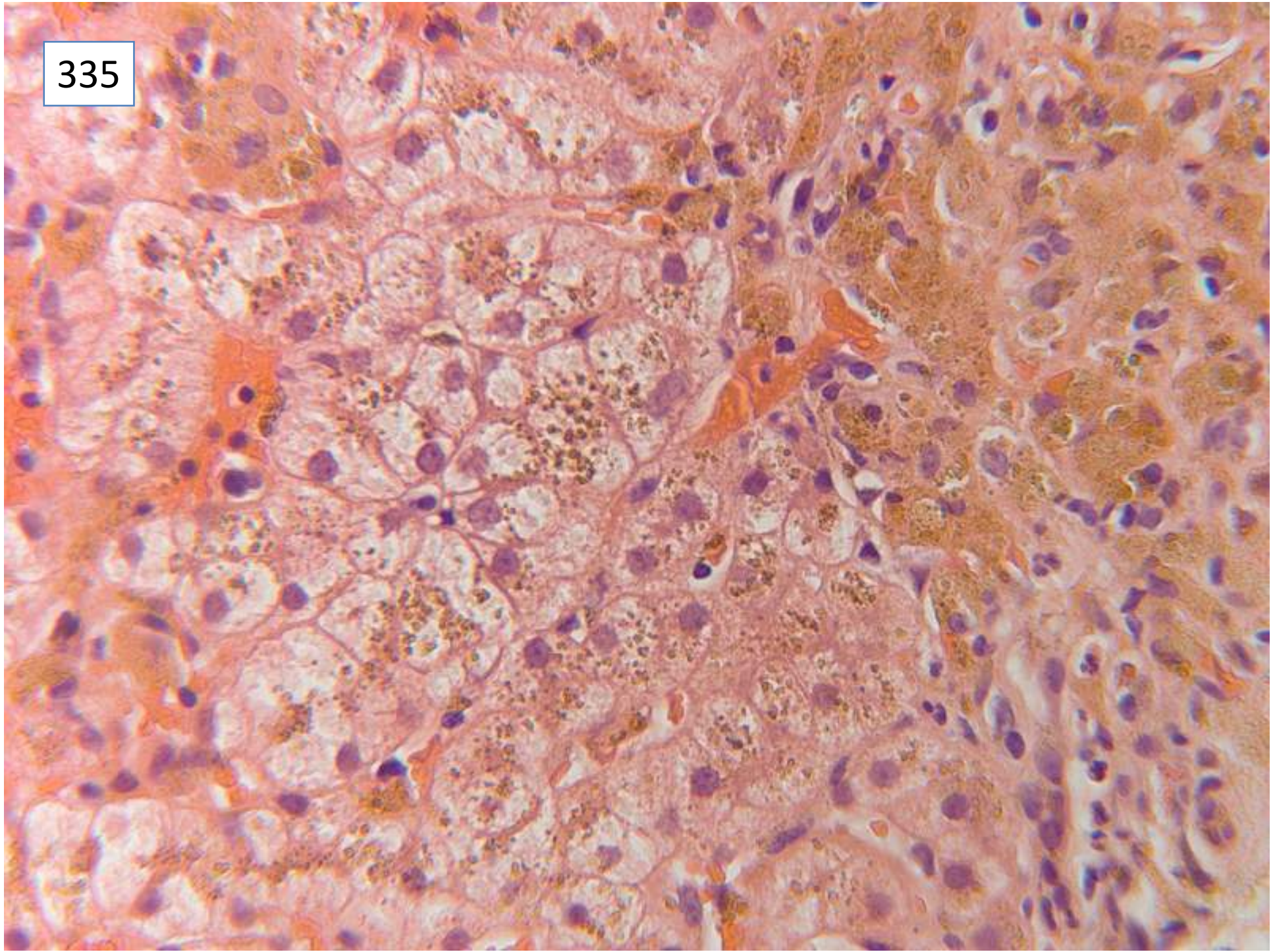
335



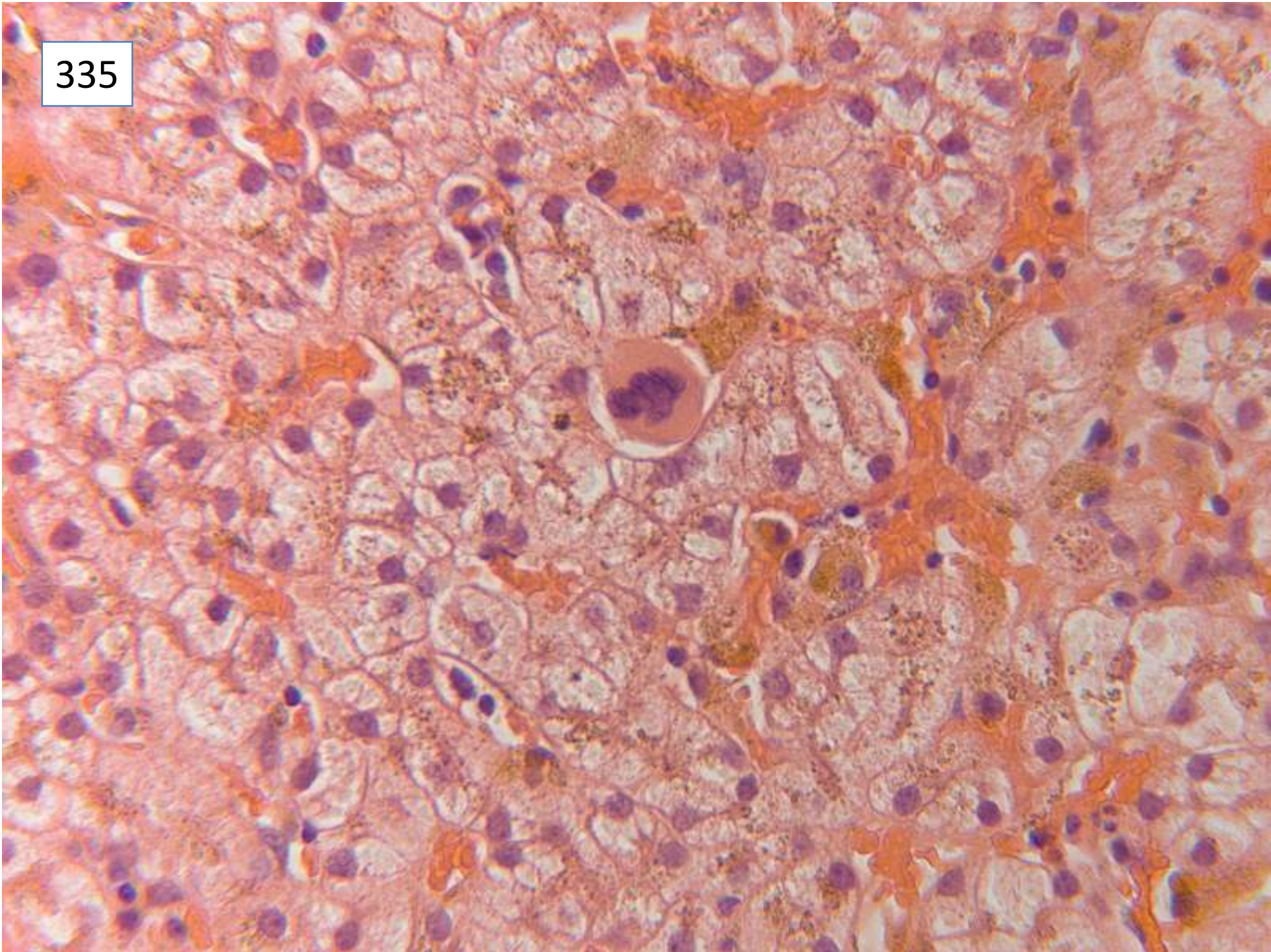
335



335



335



Responses

51 iron overload, pattern consistent with transfusion siderosis

3 iron overload NOS

1 no mention of iron

32 fibrosis present

13 no mention of fibrosis

1 'not yet cirrhosis'

7 need connective tissue stain to assess fibrosis

33 extra-medullary haematopoiesis

1 'haemosiderosis and haemochromatosis, not established cirrhosis. HFE gene studies'

Few commented on need to exclude hepatitis C

Several - need HFE genetics as well?

Scoring and discussion

Full marks for all responses including iron overload. The presence of fibrosis was not scored, since this was considered to require connective tissue stains for evaluation. There was evidence of extra-medullary haematopoiesis on the scanned slide photographed, but it is unknown whether this was present on all slides, and therefore was not required for full marks.

Discussion – it was presumed that the patient had iron overload following multiple transfusions because of thalassaemia. The presence of extra-medullary haematopoiesis supported this, as it implied insufficient bone marrow haematopoiesis to keep pace with haemolysis from thalassaemia. Clinicopathological discussion is required to confirm transfusions.

The distribution of iron in macrophages/Kupffer cells as well as hepatocytes can also be seen in some inborn errors of iron metabolism e.g. **ferropontin/ferroportin** deficiency. Specialist investigations for this are not currently available in the UK – some members had sent samples to Italy for further investigation. Genetic tests for haemochromatosis would only be indicated if the iron could not be explained by multiple transfusions.

Submitting pathologist's diagnosis: Grade 4 siderosis, Ishak stage 2 fibrosis. Extra-medullary haematopoieses, consistent with stated history.

Case 336

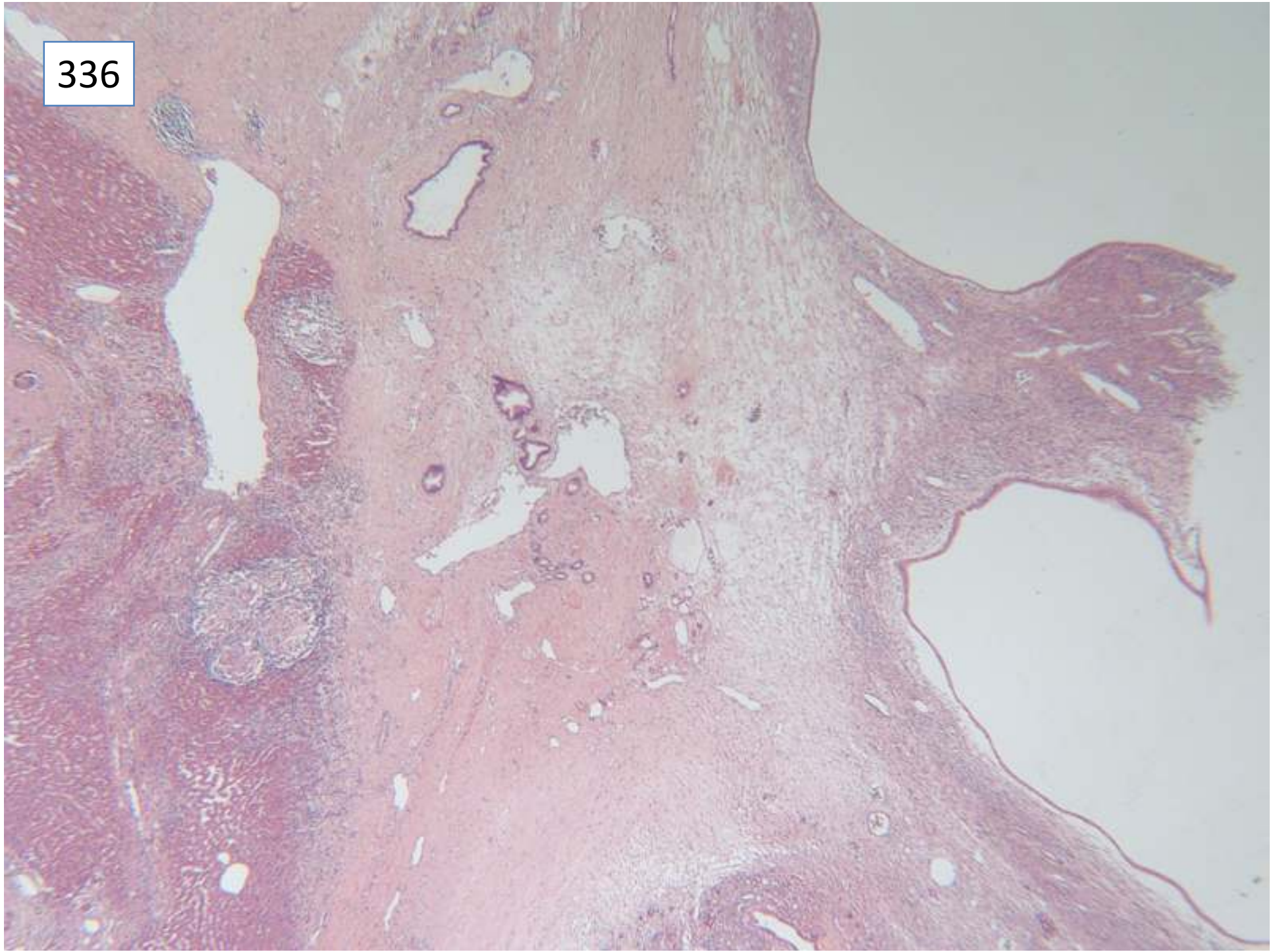
Female 34 years

Non-anatomical resection. Previous partial excision for simple cyst. This is completion excision of remainder.

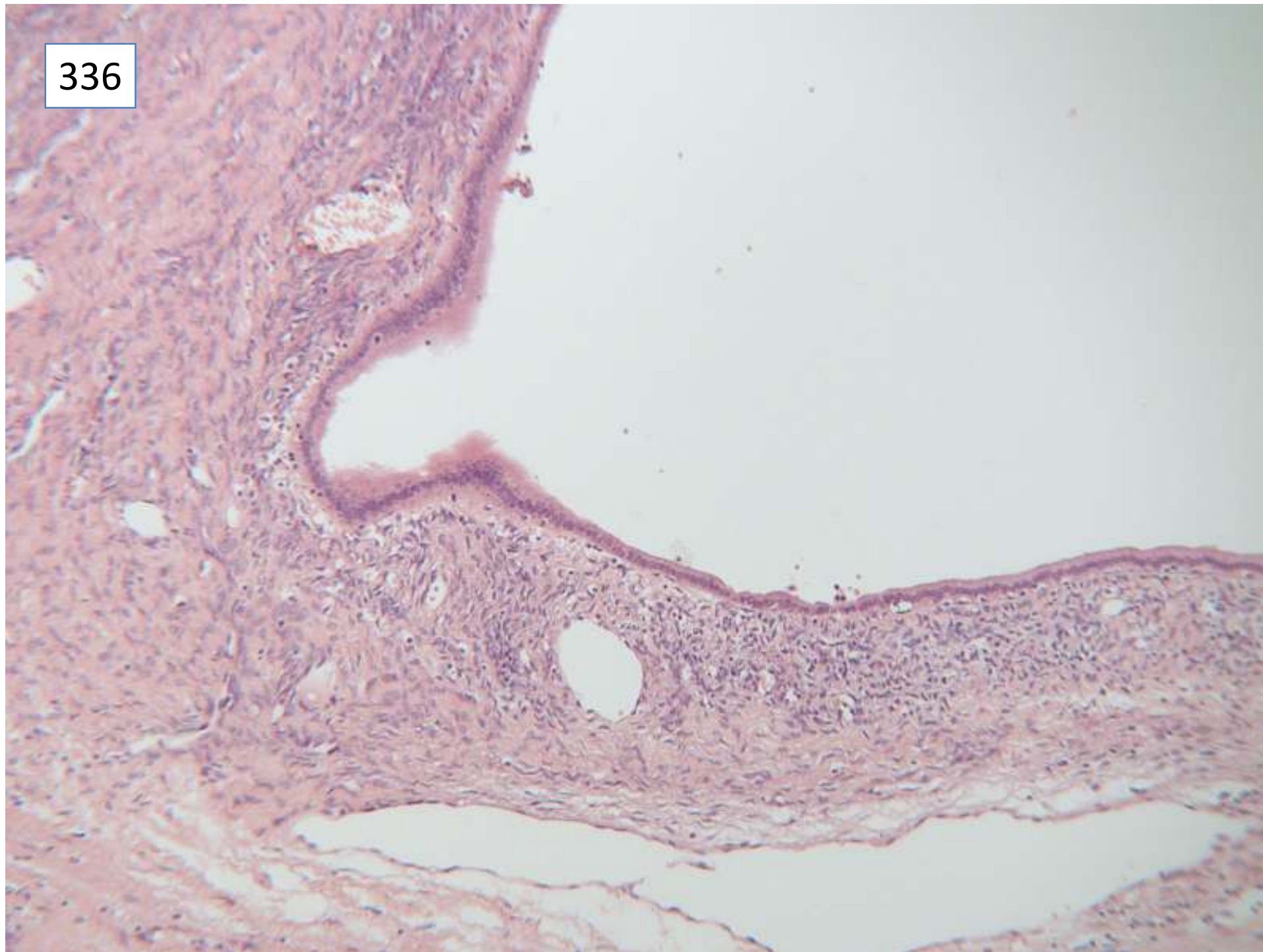
Specimen: Liver and gall bladder

Macroscopic description: A- liver cyst-the specimen weighs 260 grams, comprising previously opened thick walled unilocular cyst 13 cms in diameter, received in a collapsed state without contents.

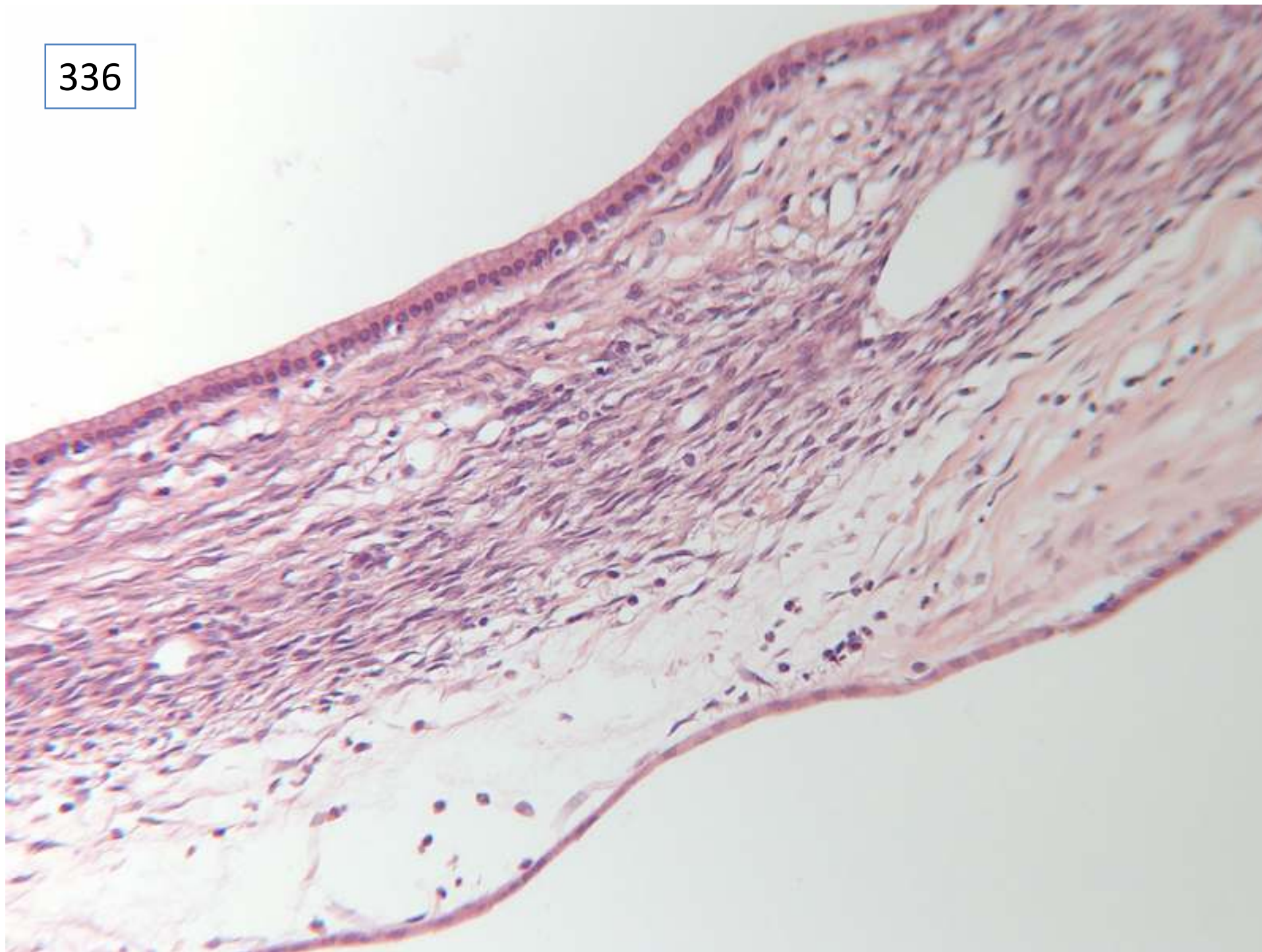
336



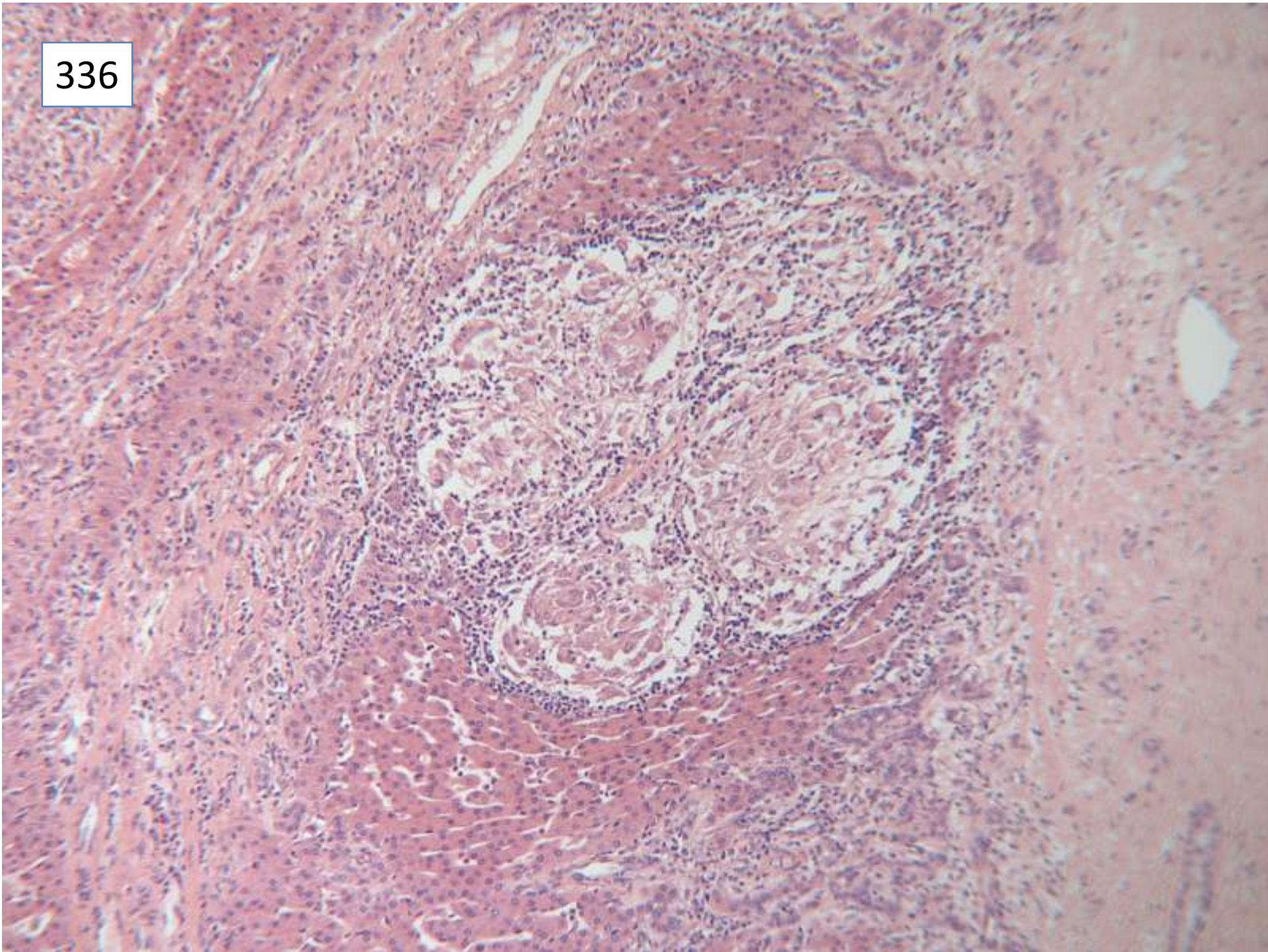
336



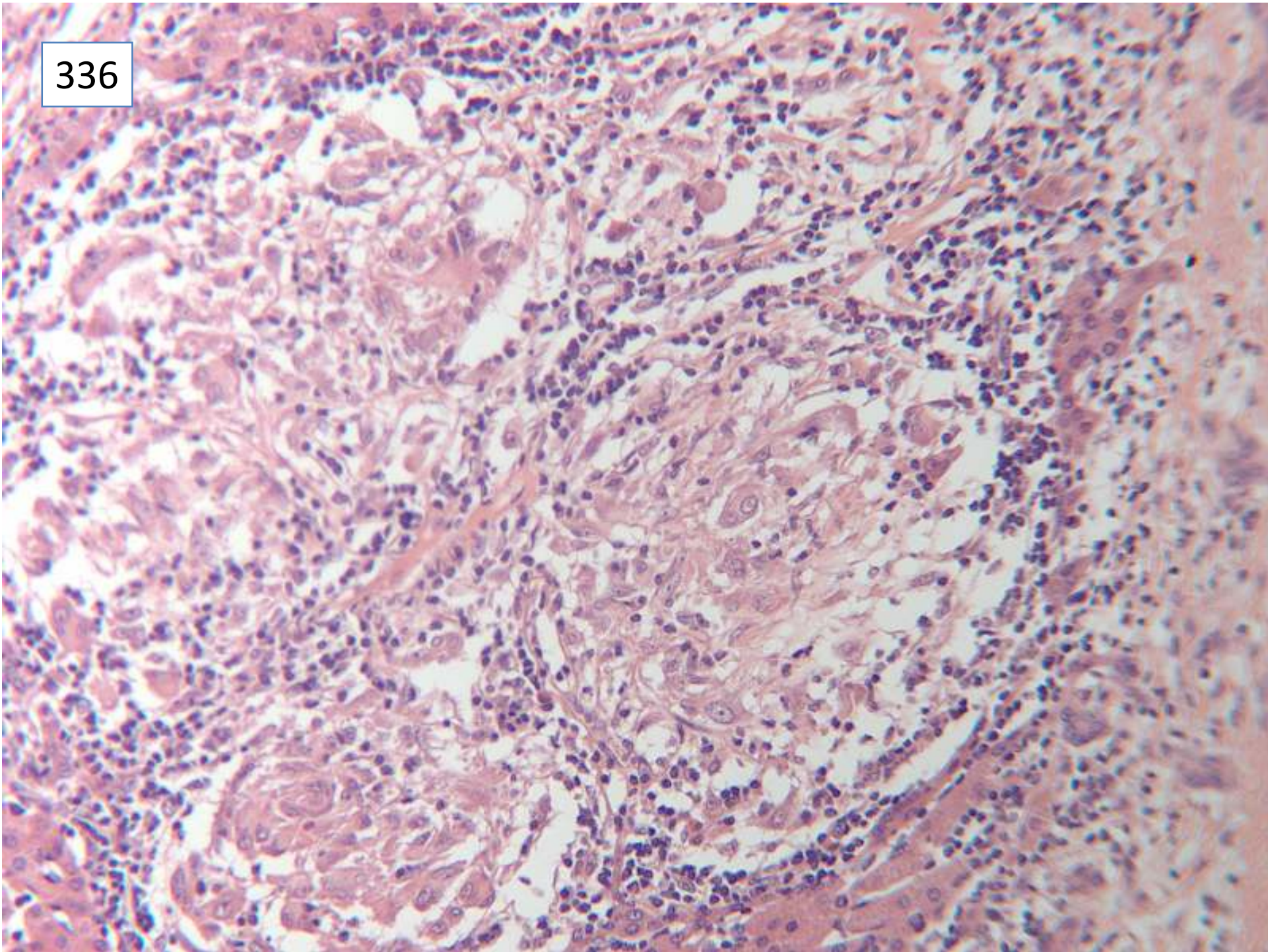
336



336



336



Responses

42 hepatobiliary cystadenoma, with specialised/mesenchymal stroma

7 hepatobiliary cystadenoma (no mention of stroma)

1 mucinous cystadenoma

1 benign biliary cyst, ? hamartomatous

1 solitary unilocular cyst, biliary epithelium

2 endometriotic cyst

1 adenofibroma or mucinous cystadenoma

24 granuloma/granulomatous hepatitis

27 no mention of granuloma

7 further medical investigations suggested for granulomatous inflammation

Several attributed granuloma to previous surgery.

Scoring and discussion

This cyst wall showed cellular stroma characteristic of hepatobiliary cystadenoma.

Half the responses did not include mention of the granuloma in the adjacent liver tissue; it is possible that this feature was not present in all sections, and so is not included in the scoring

Submitting pathologist's diagnosis: hepatobiliary cystadenoma with mesenchymal stroma

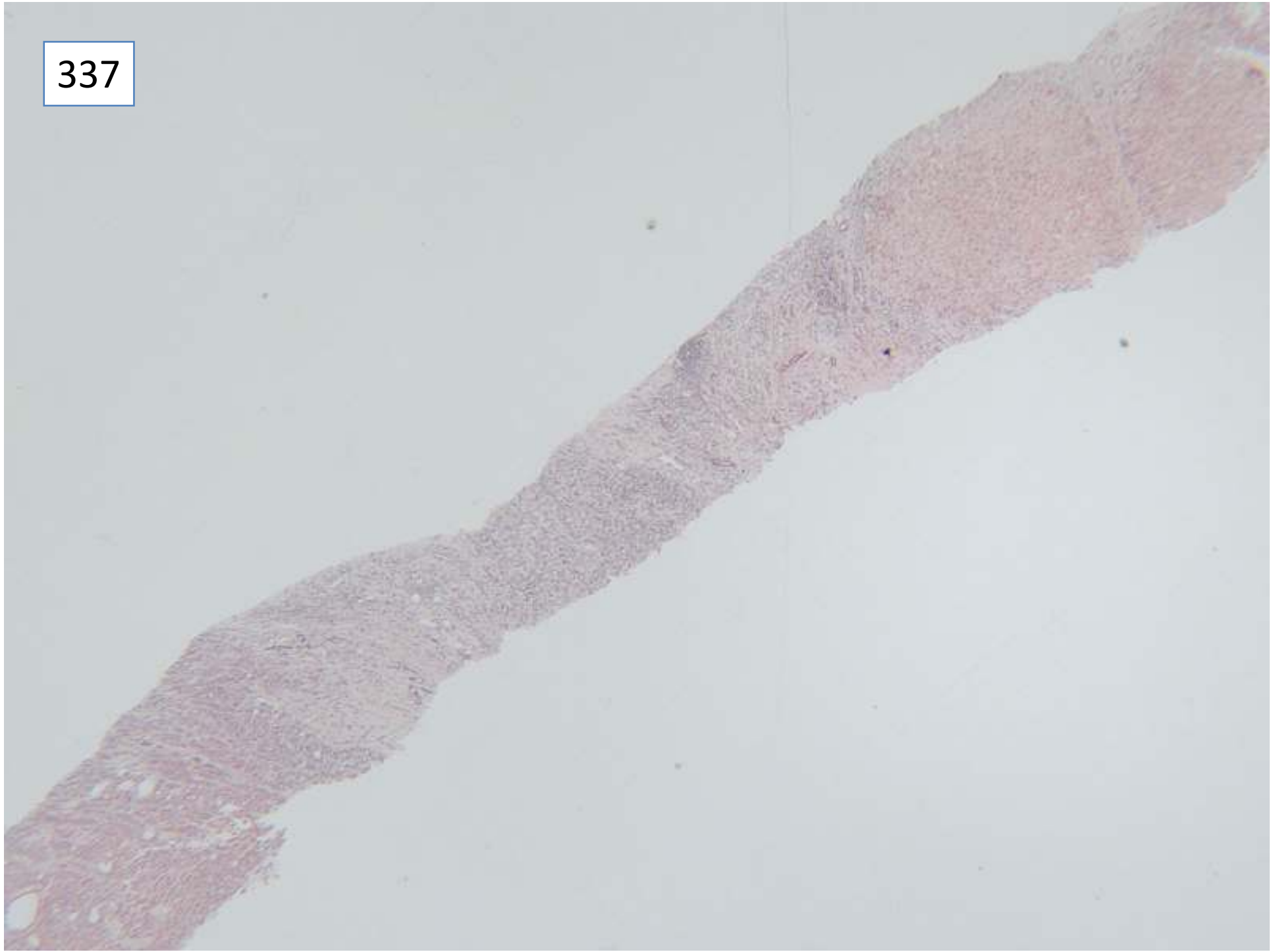Case 337

Female 50 years

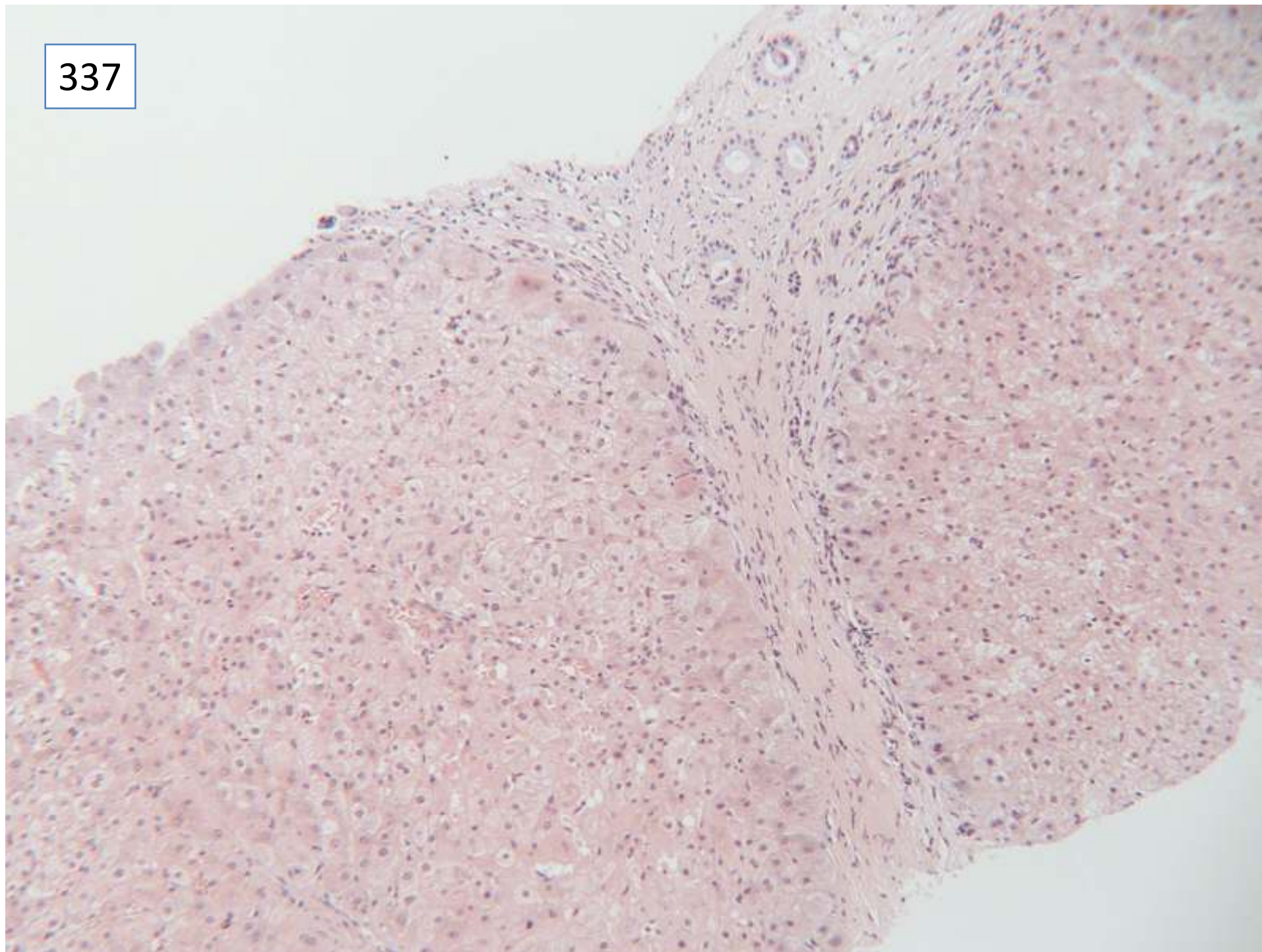
Hepatitis C, plus cirrhosis secondary to alcohol.

1cm hypoechoic lesion segment 4, core biopsy

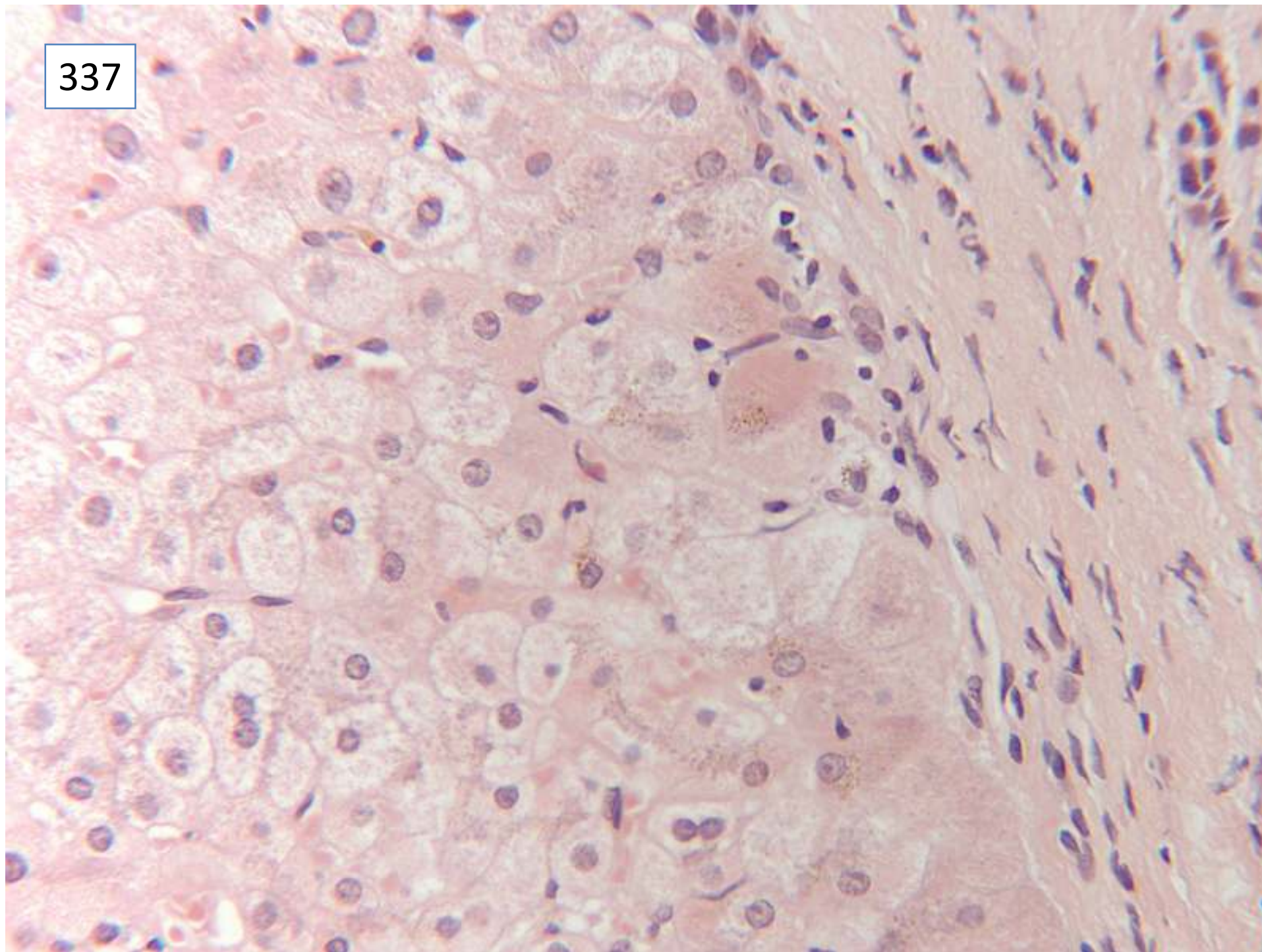
337



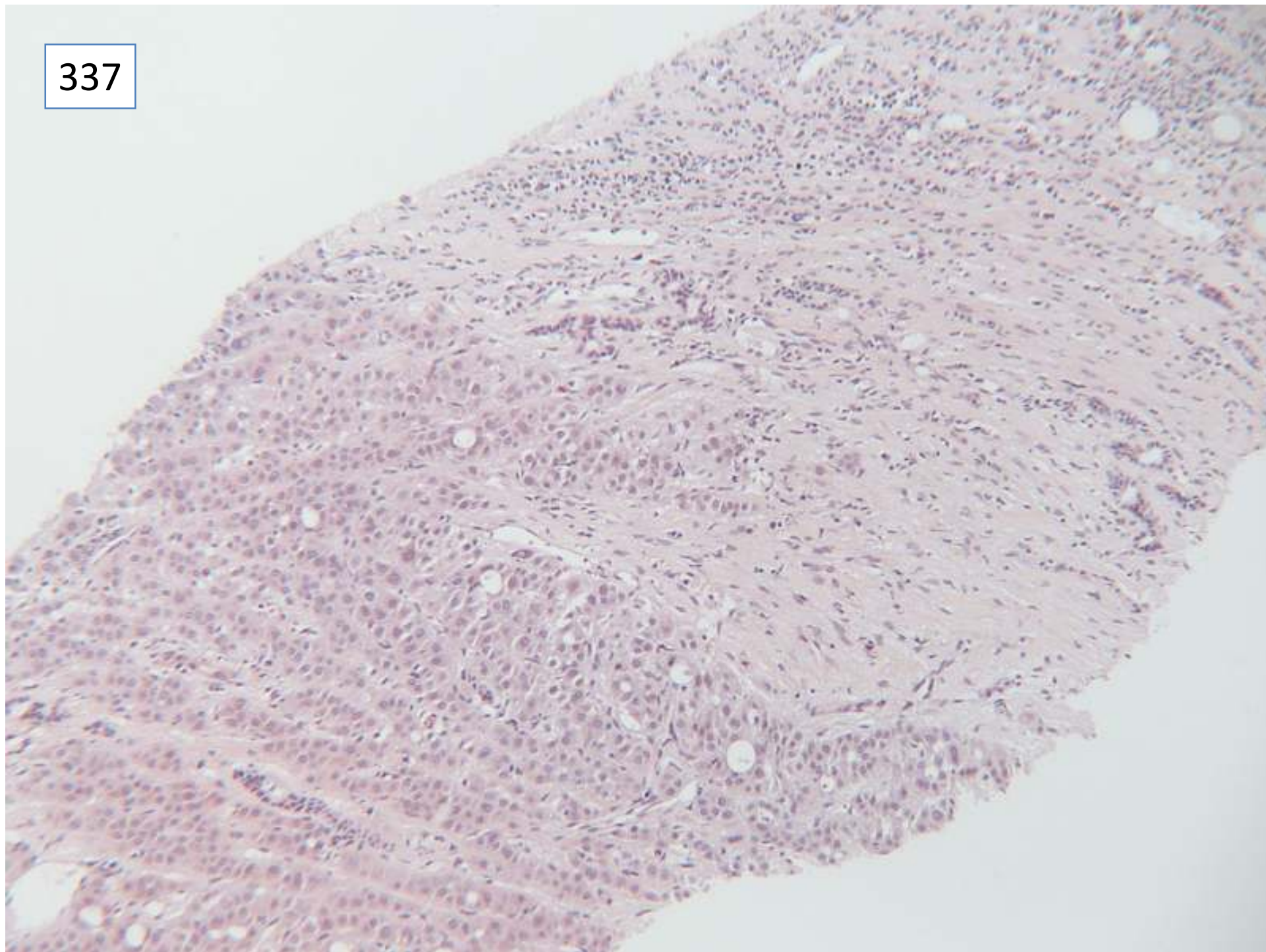
337



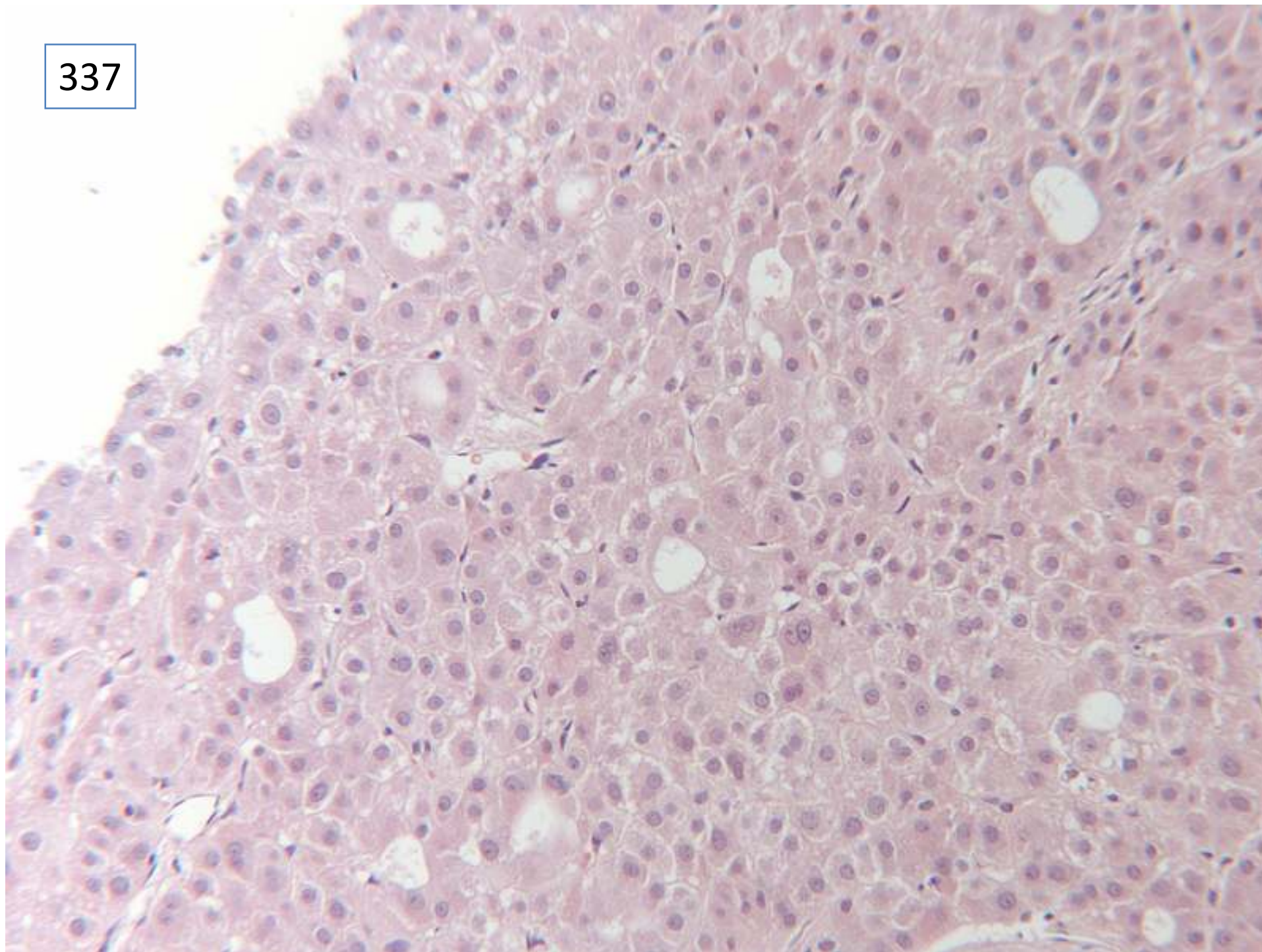
337



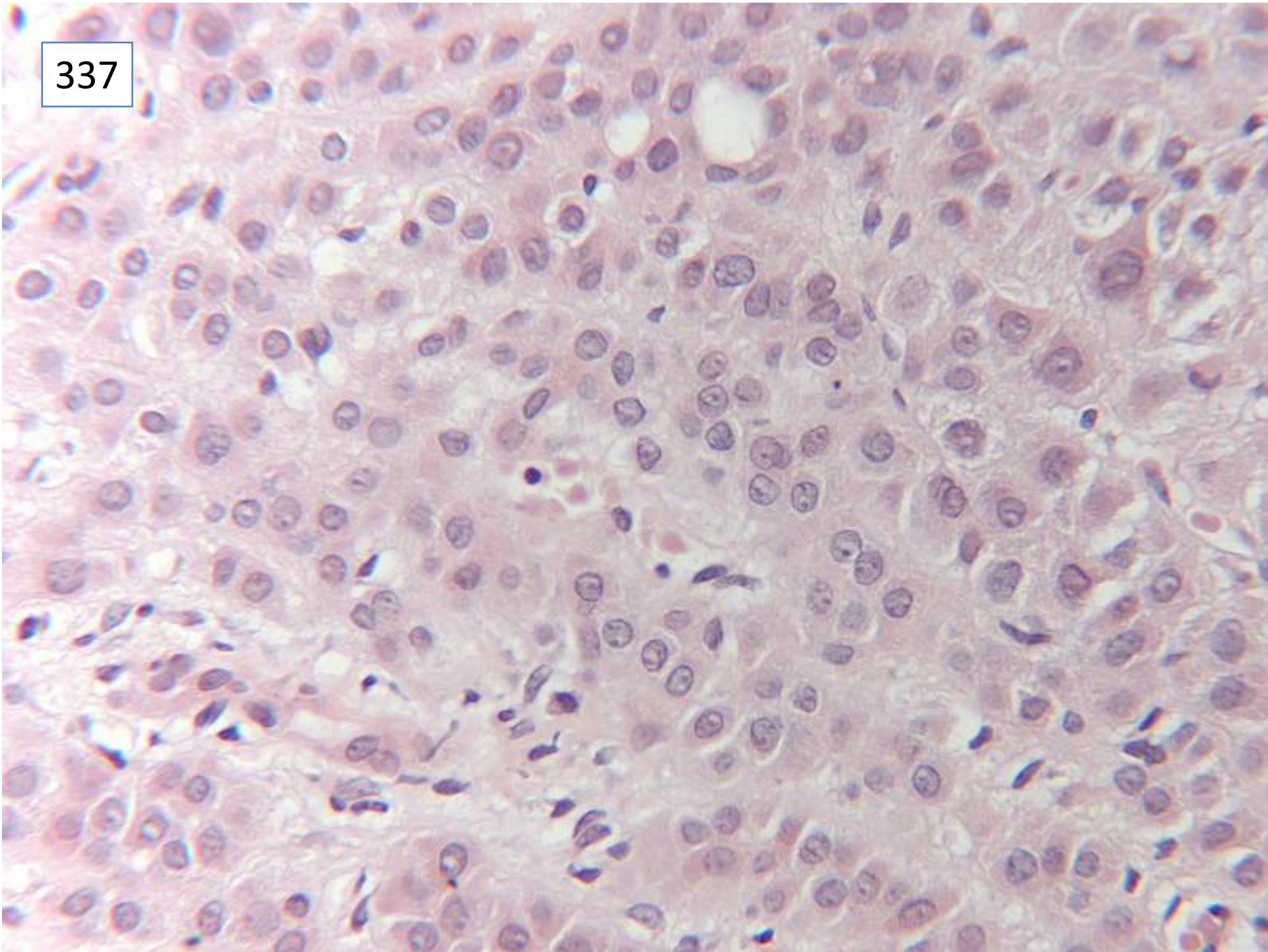
337



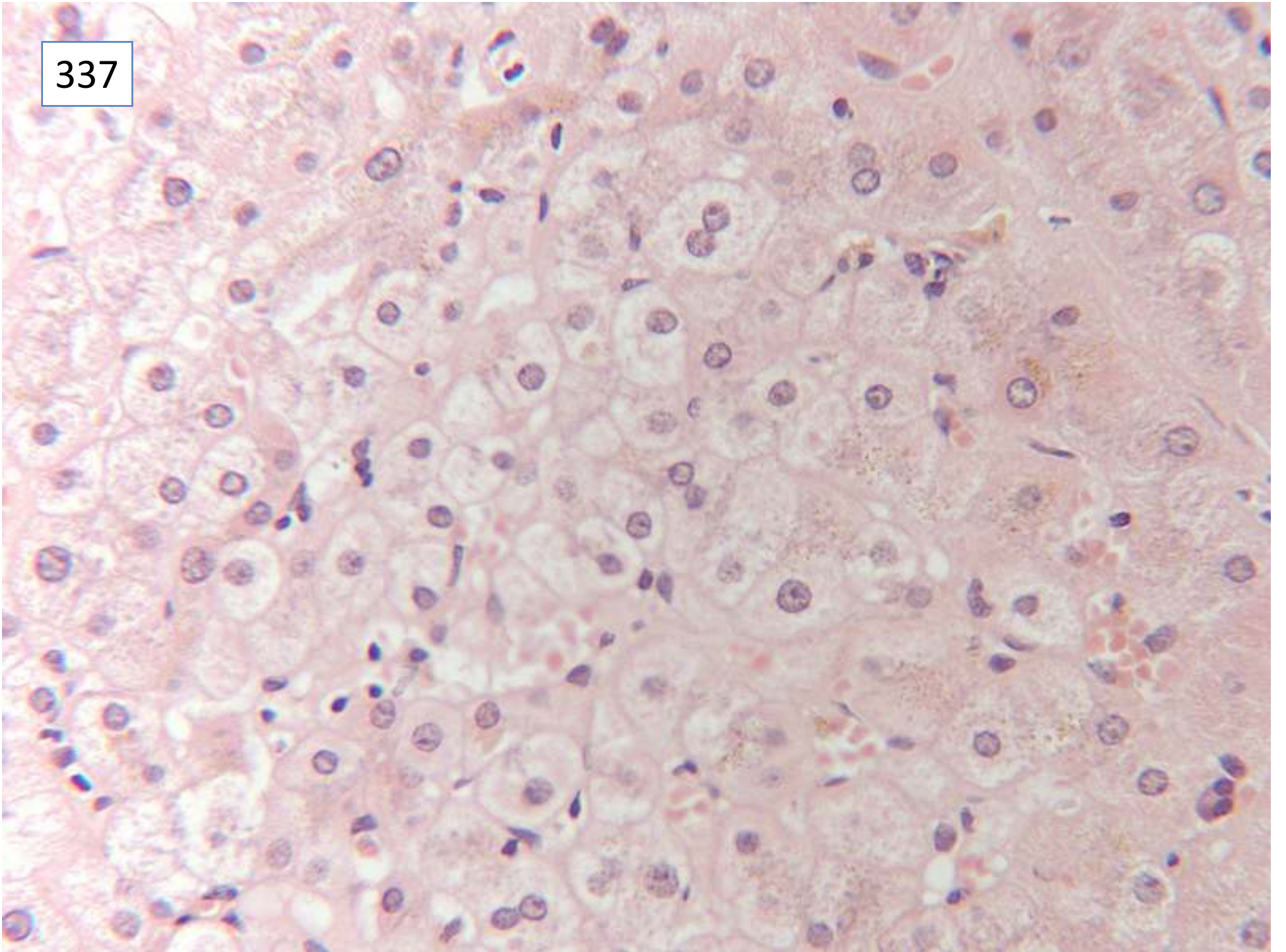
337



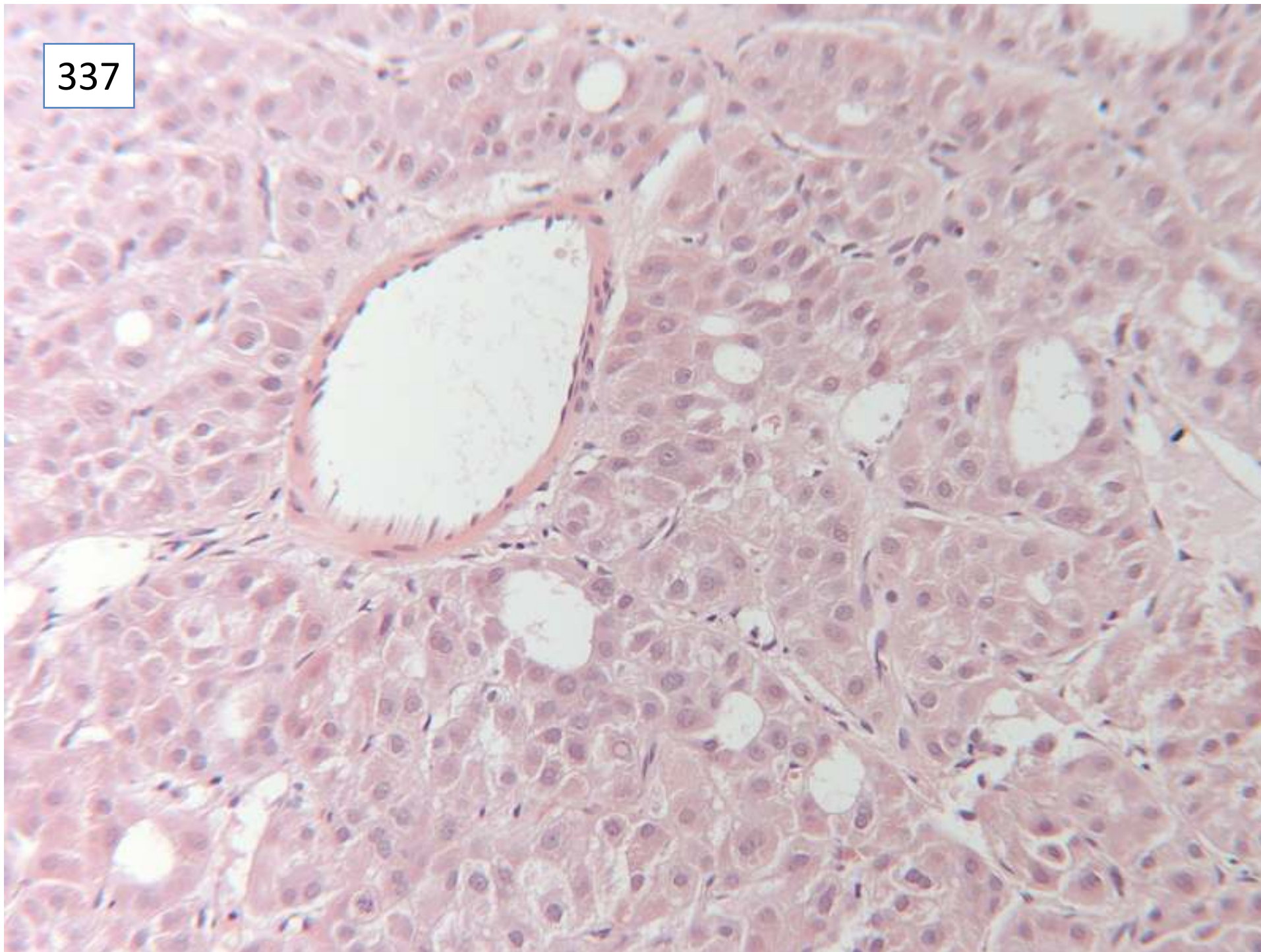
337



337



337



Responses

49 cirrhosis

5 no mention of cirrhosis

44 hepatocellular carcinoma

of which: 14 well differentiated

5 moderately differentiated

25 no grade included

1 probable HCC

7 dysplastic nodule suspicious of HCC

1 liver cell dysplasia (nil else)

2 adenoma vs. Well differentiated HCC

10 ? iron overload, needs Perl's stain

Scoring and discussion

Both the presence of background cirrhosis and of hepatocellular carcinoma in the biopsy were required for full marks. There were considered to be sufficient features of HCC (cytological and architectural) to make the diagnosis on this slide. The presence of arteries within the lesion, the cytology compared with the hepatocytes in the background liver, and the large rosettes/pseudo-acinar pattern were features that supported the diagnosis of HCC.

The differential is with dysplastic nodule, and not with adenoma, in the context of a cirrhotic liver.

This patient went on to have radio-frequency ablation, but subsequently developed several other small nodules. For a while she was within transplant criteria (up to 3 lesions <3cm diameter).

Submitting pathologist's diagnosis: cirrhosis, well differentiated hepatocellular carcinoma.

The end